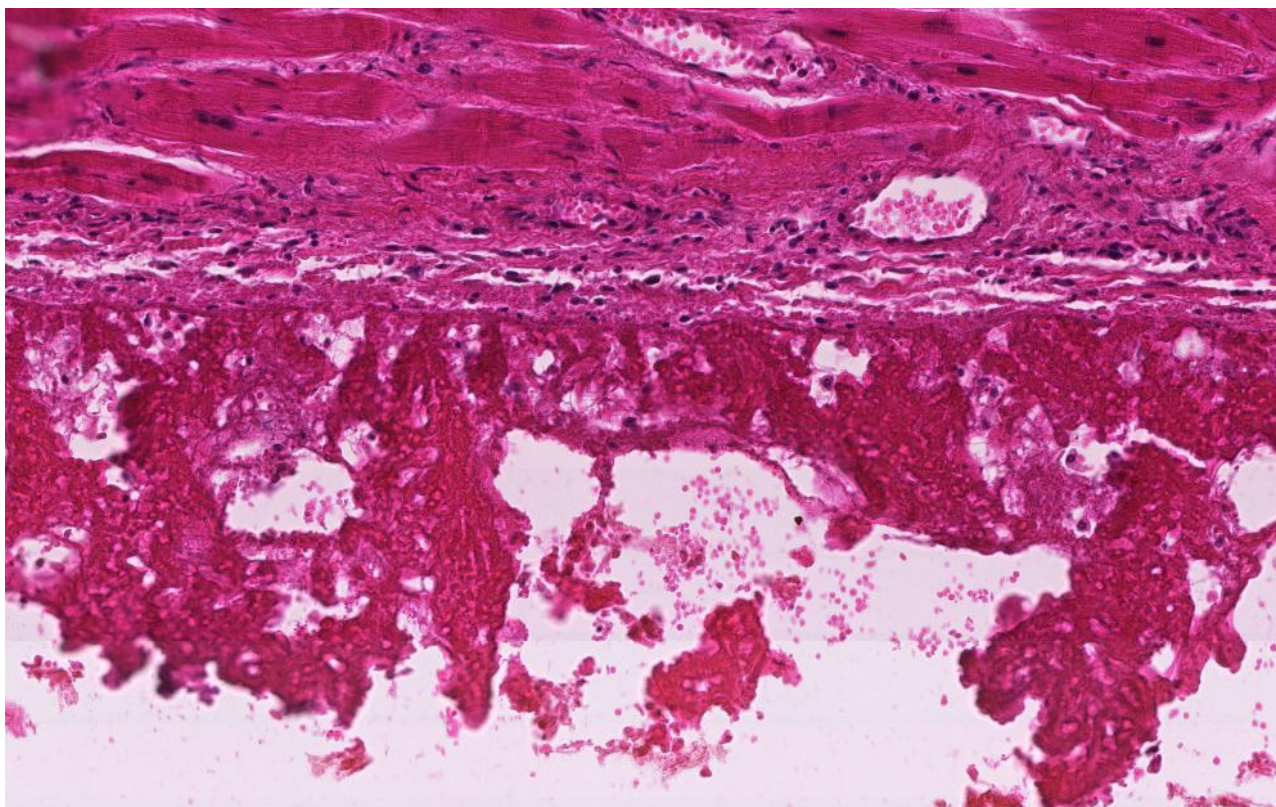
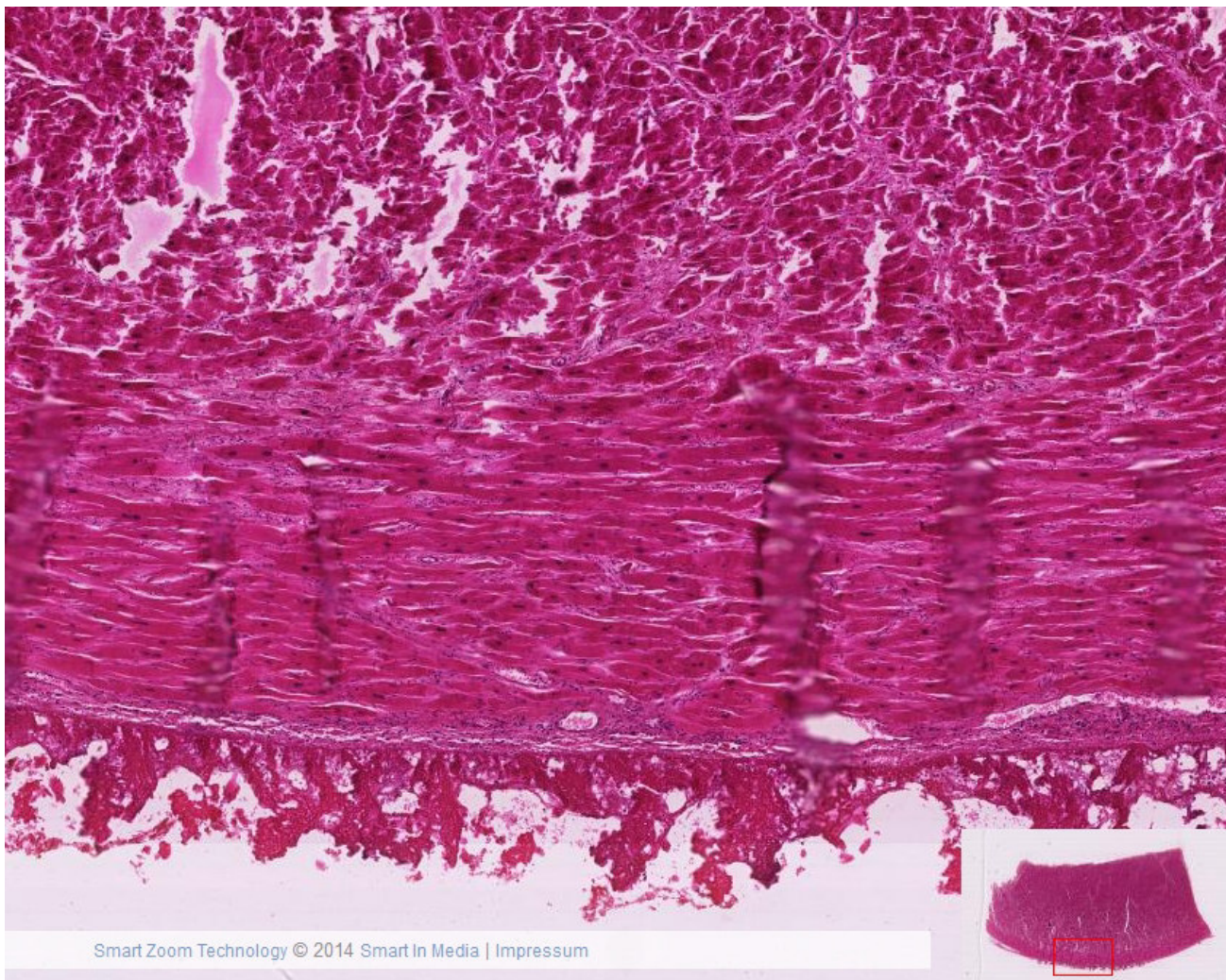
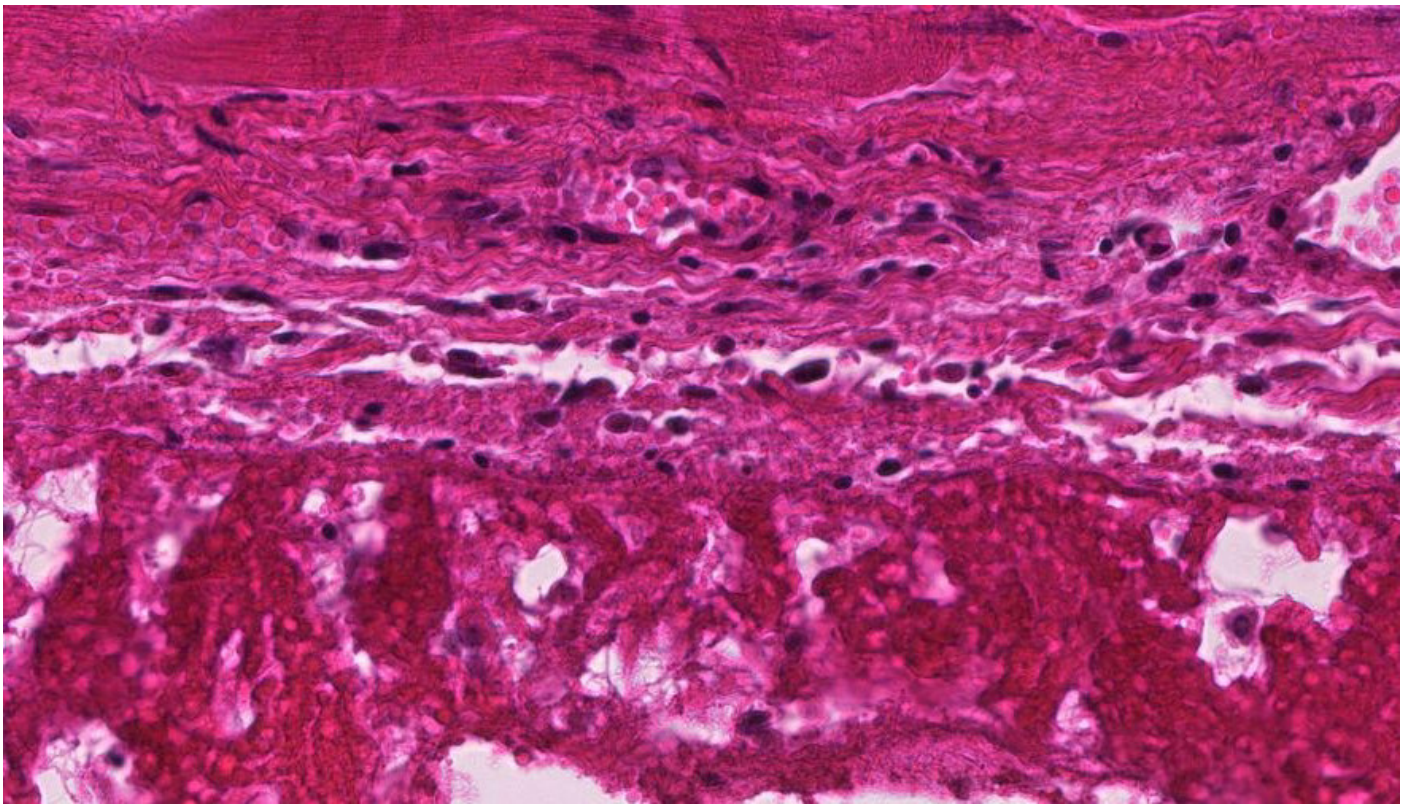
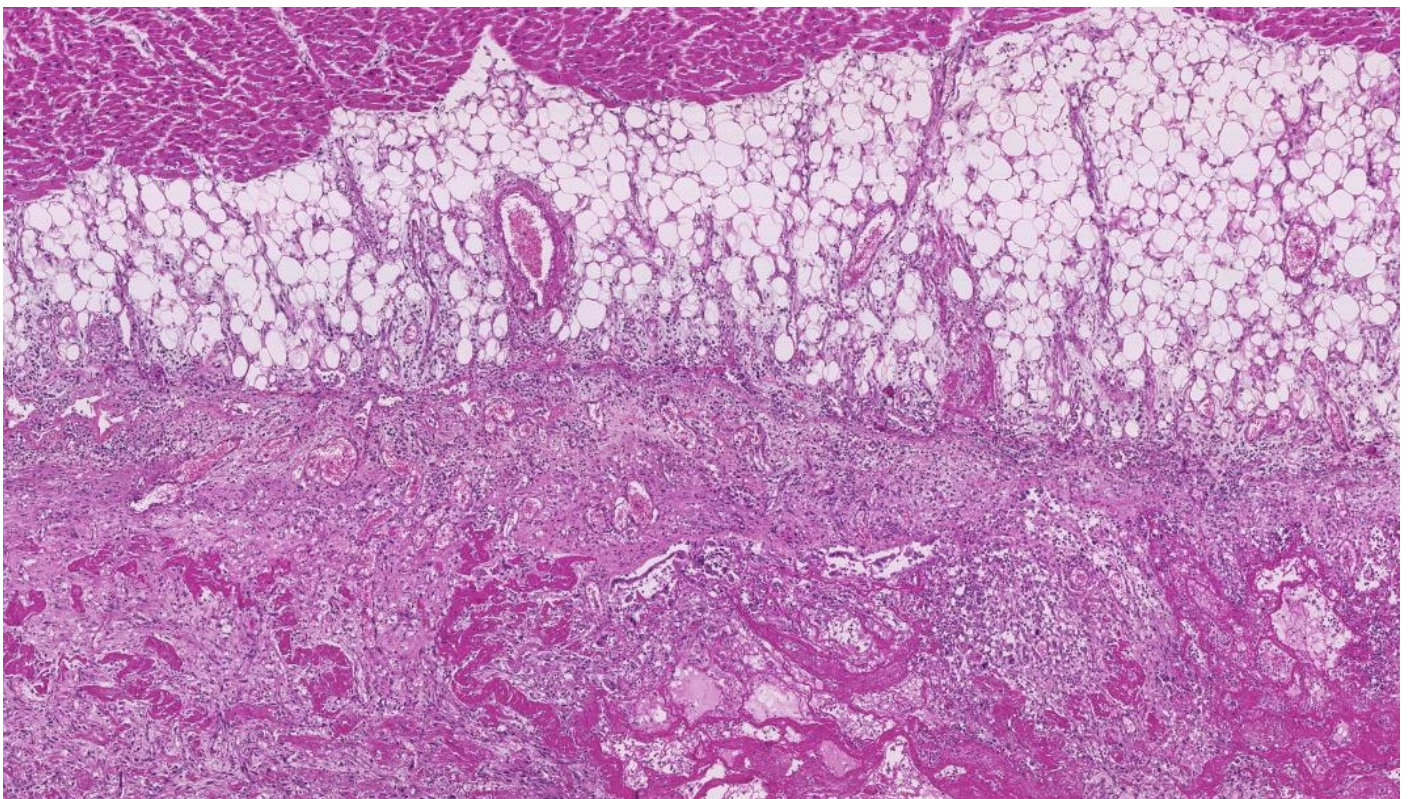
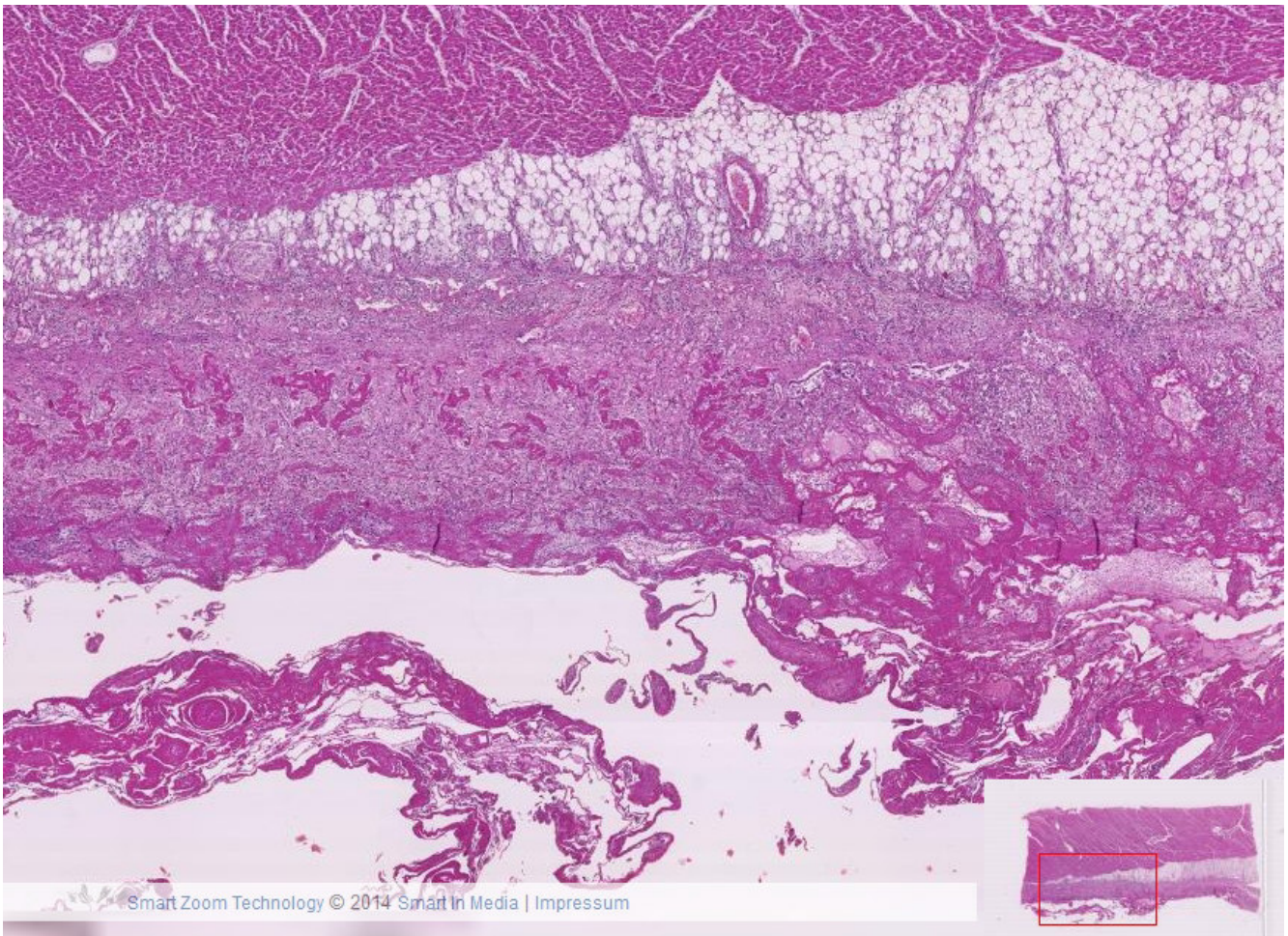


### III-1 Akute fibrinöse Perikarditis

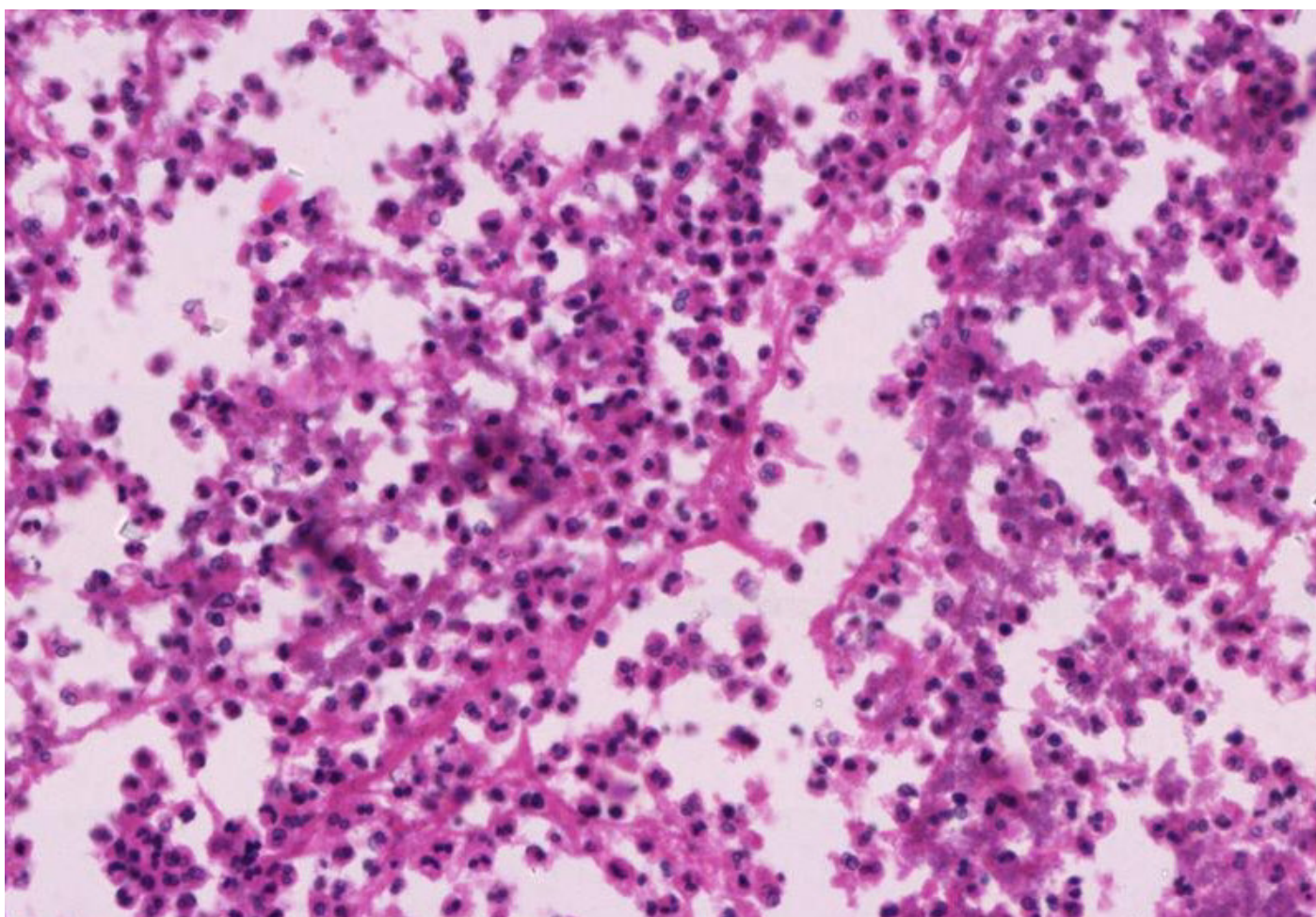
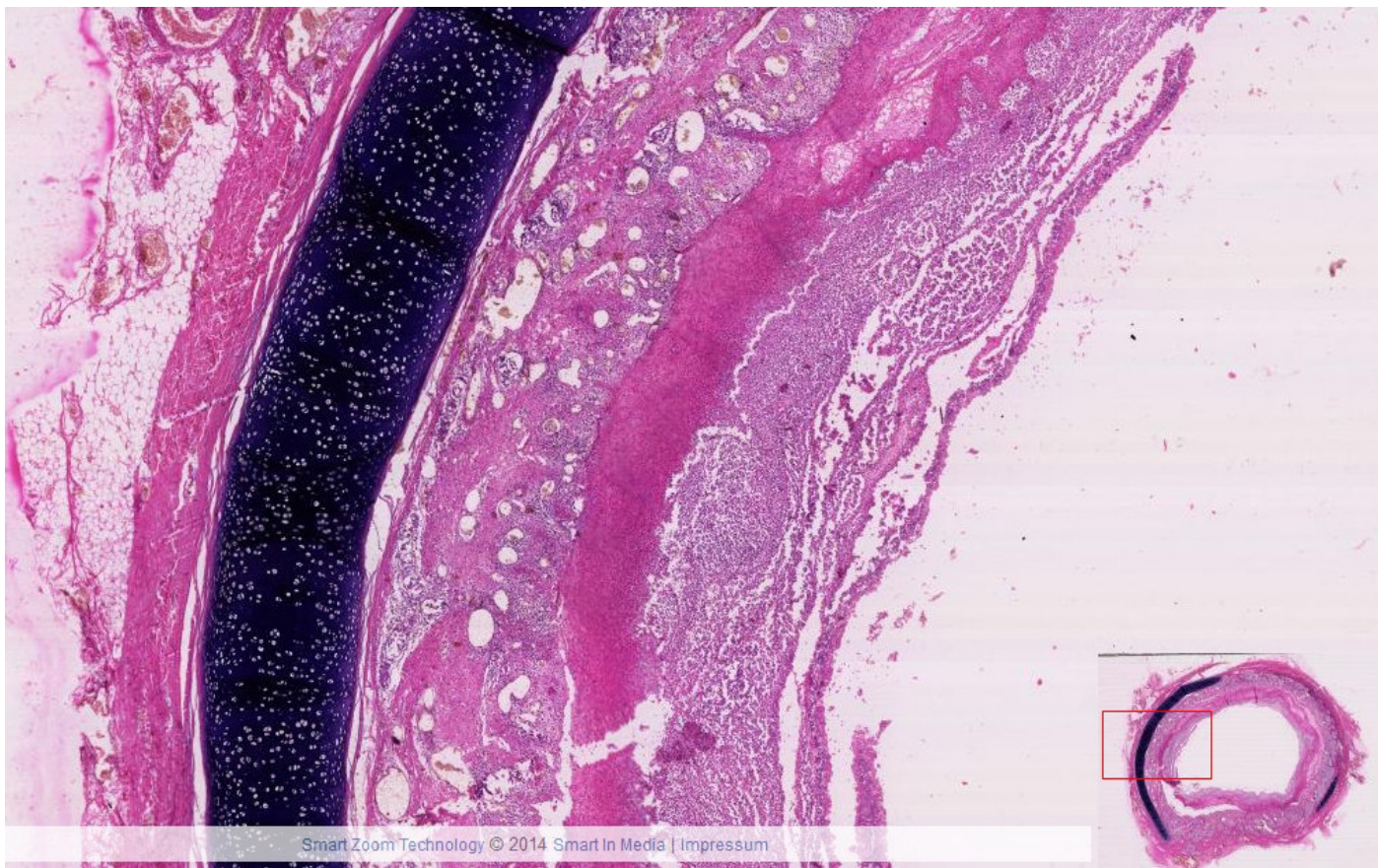


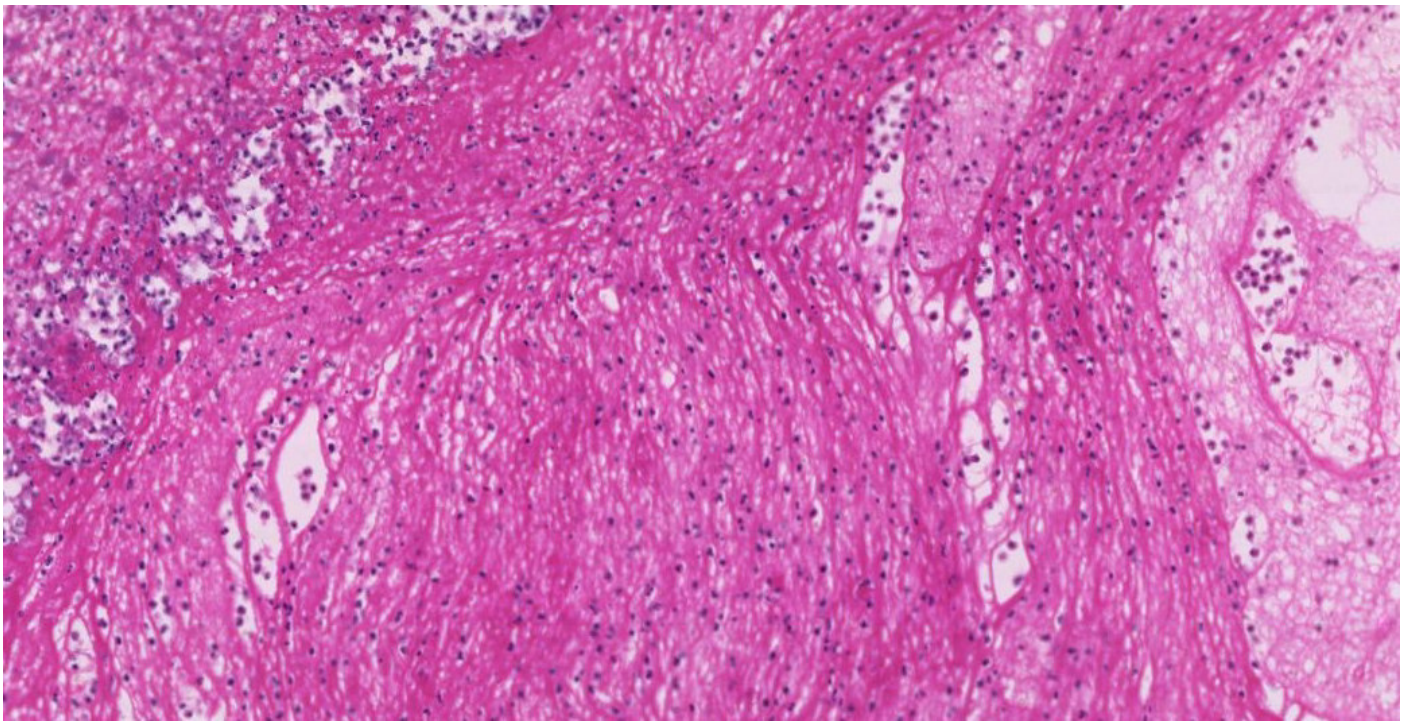


### III-2 Fibrinöse Perikarditis in Organisation

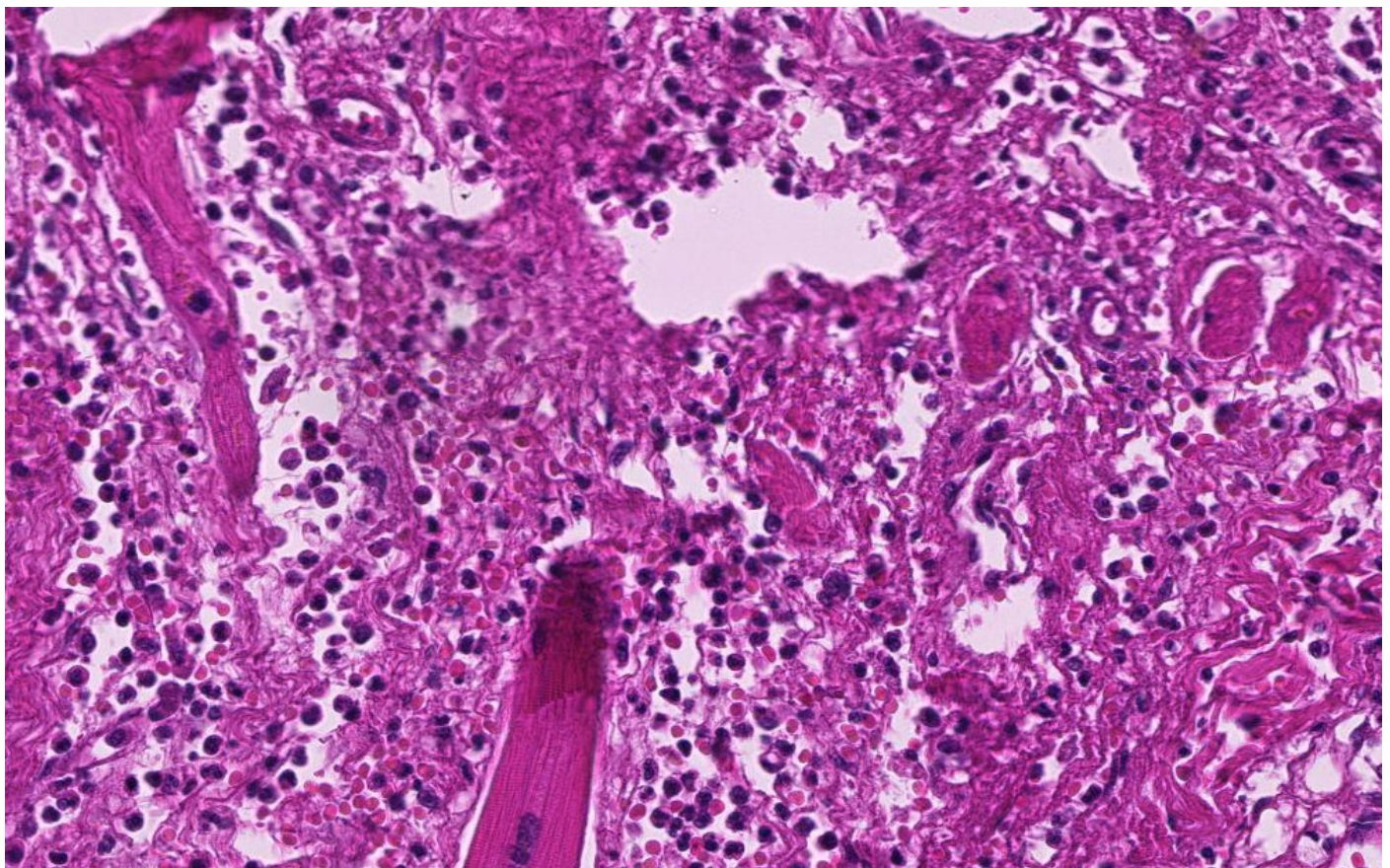
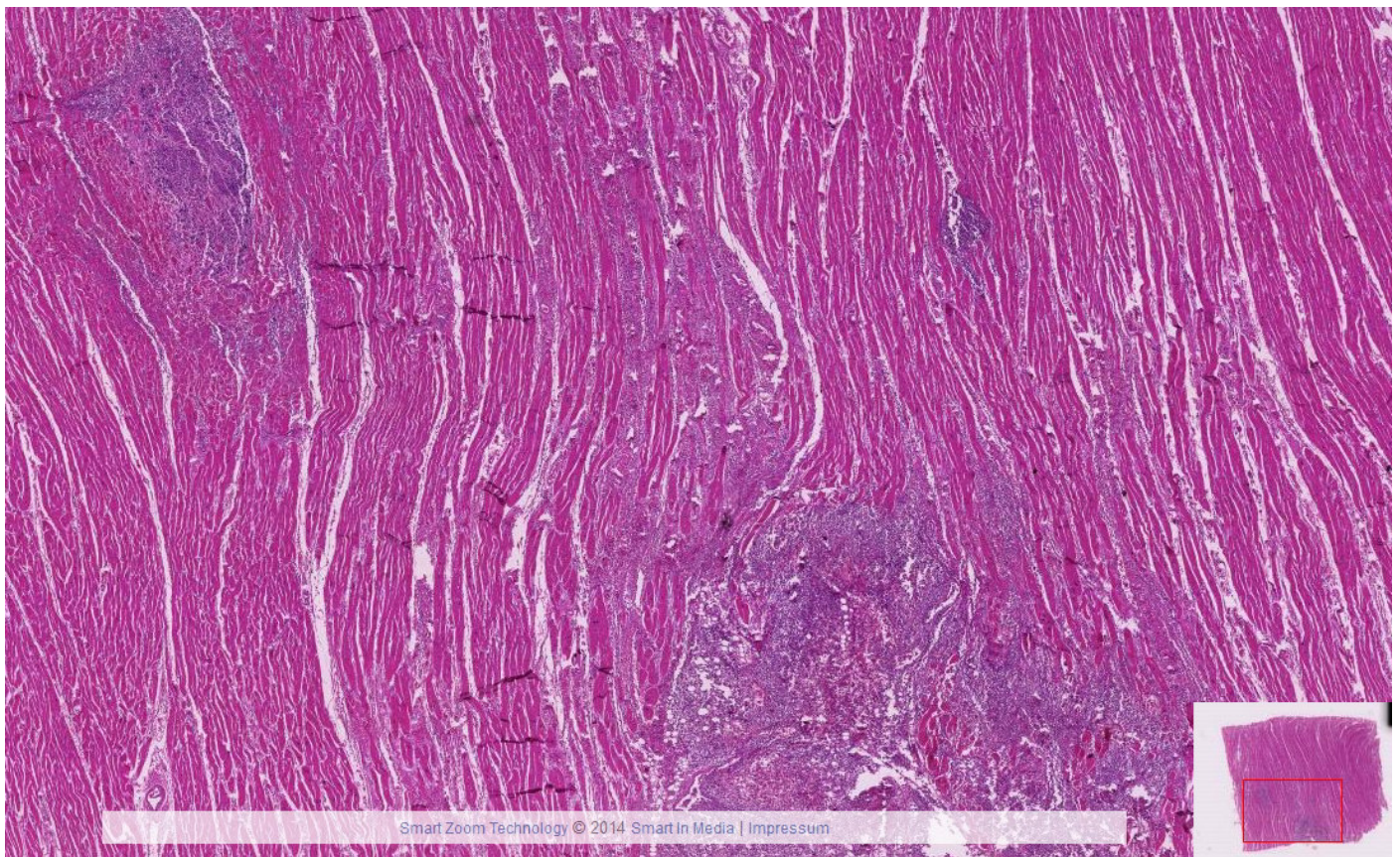


### III-3 Pseudomembranöse Tracheitis

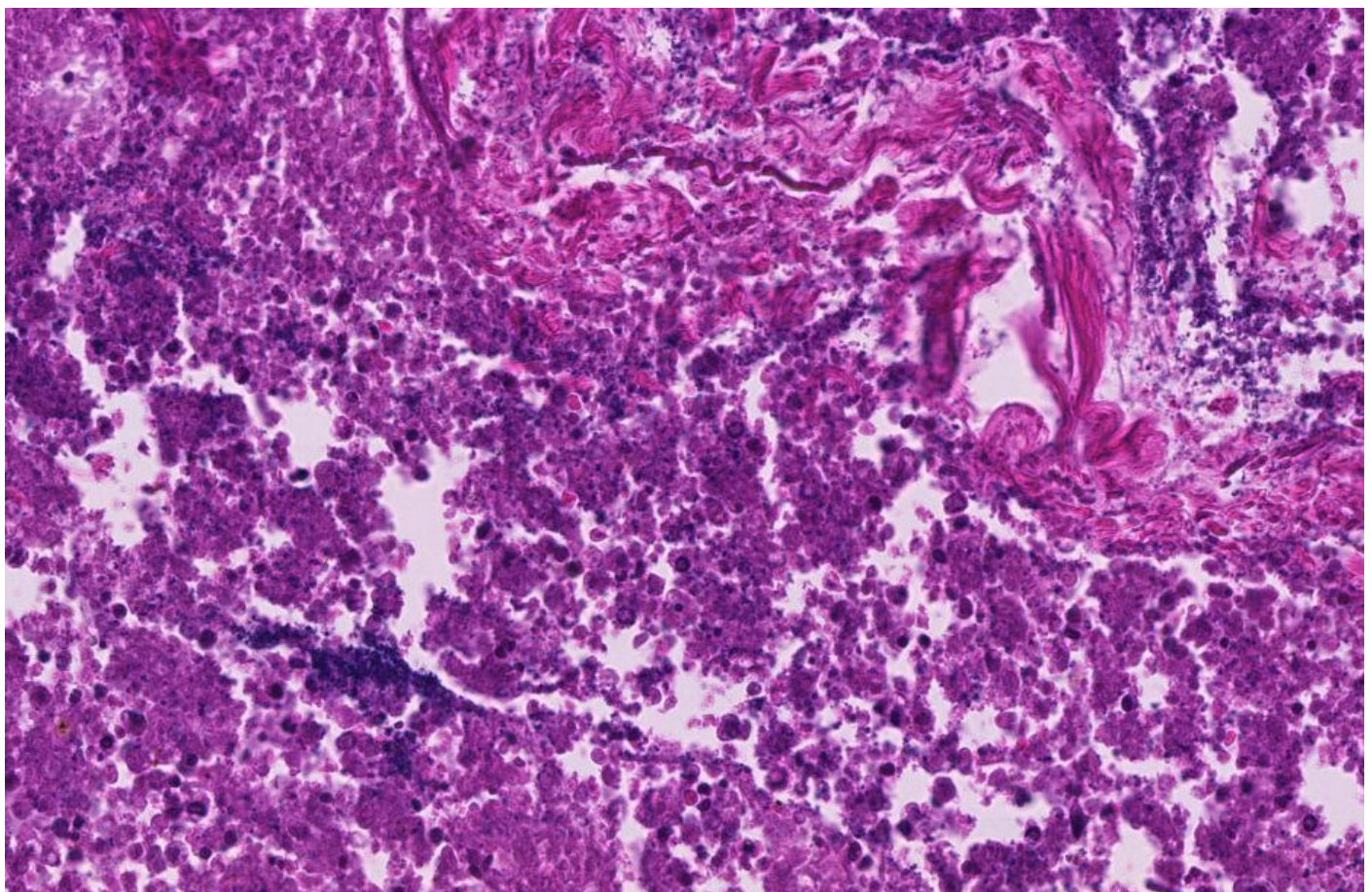
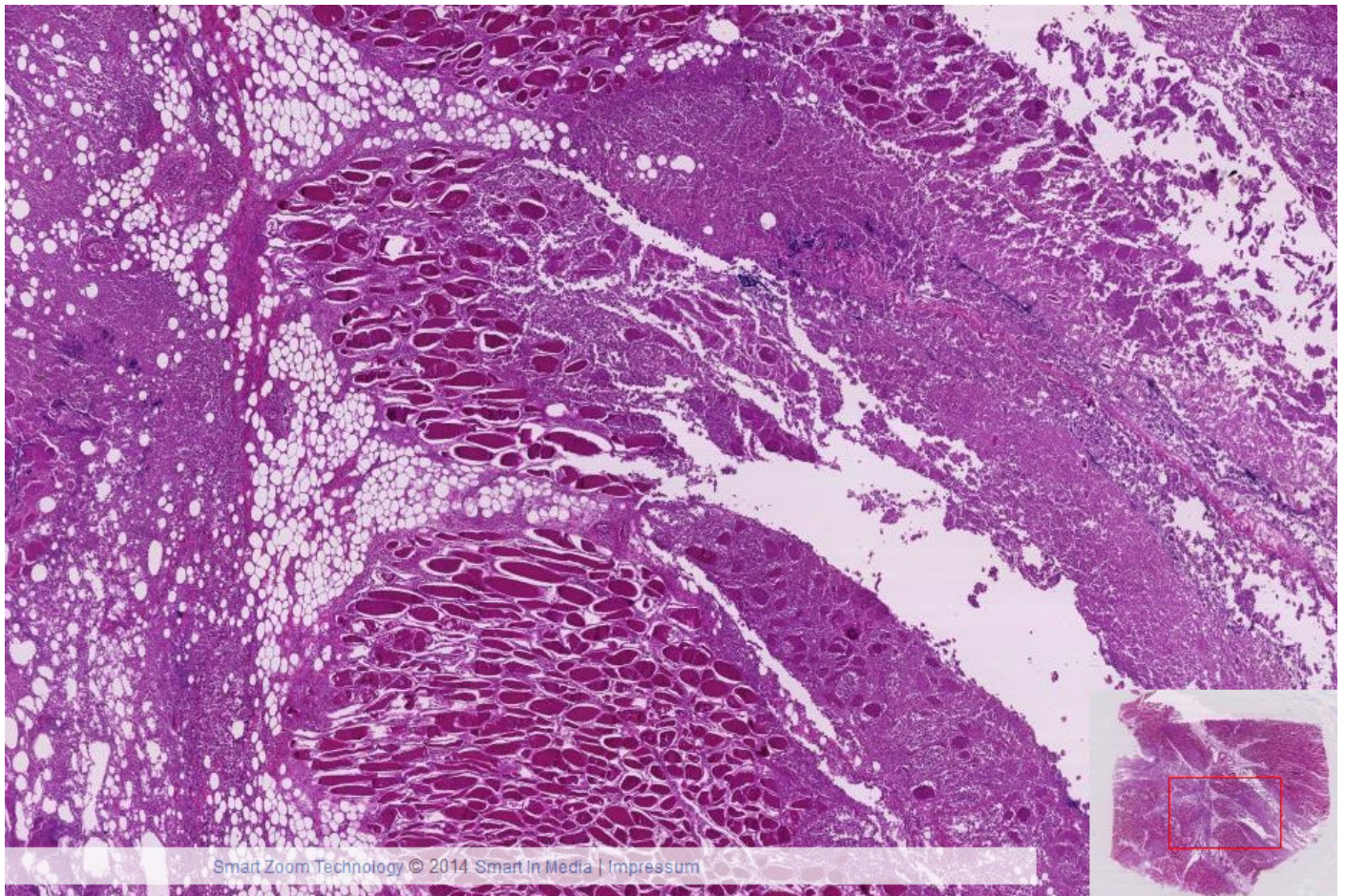




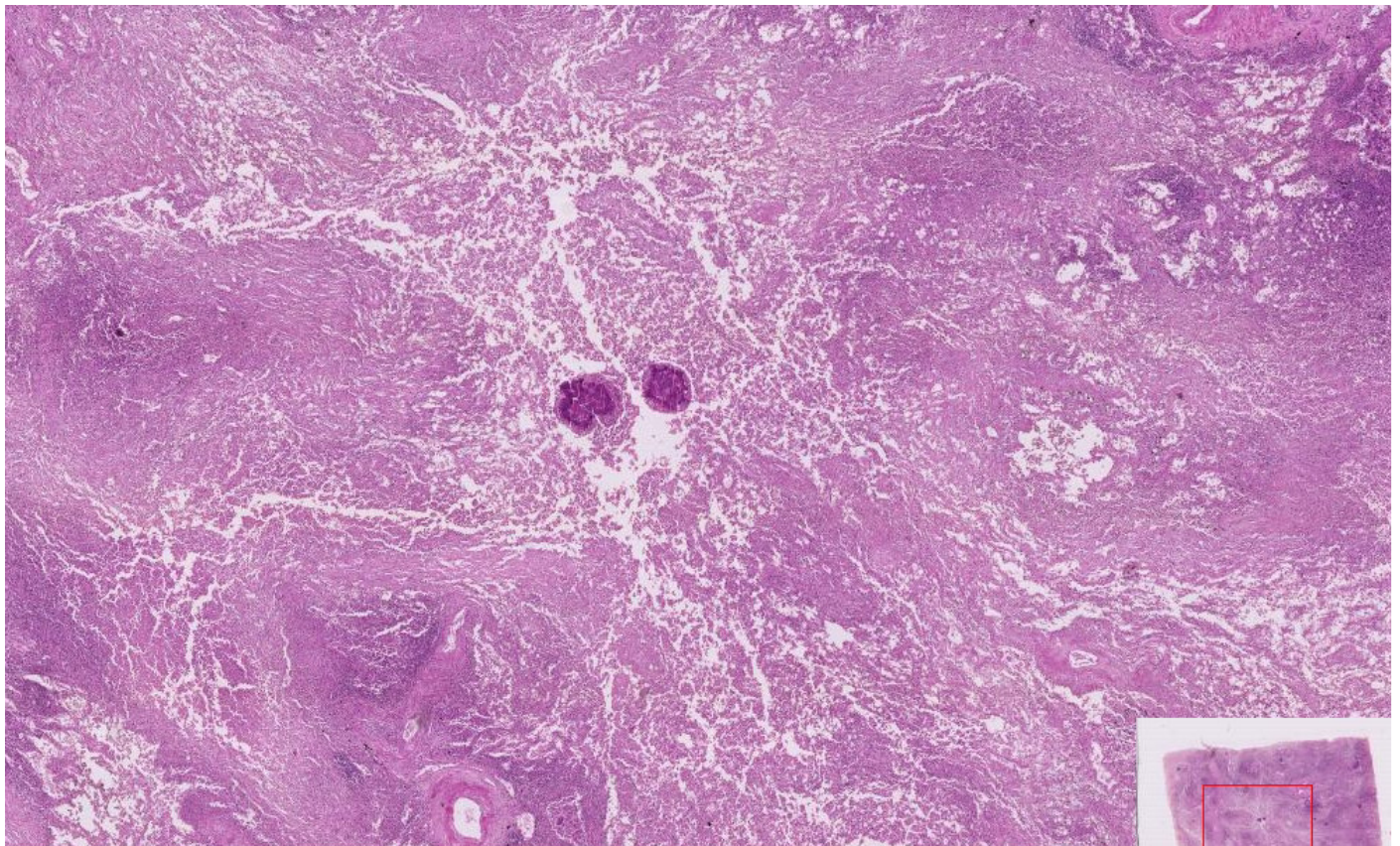
### III-4 Pyämische metastatische Abzesse Herzmuskel



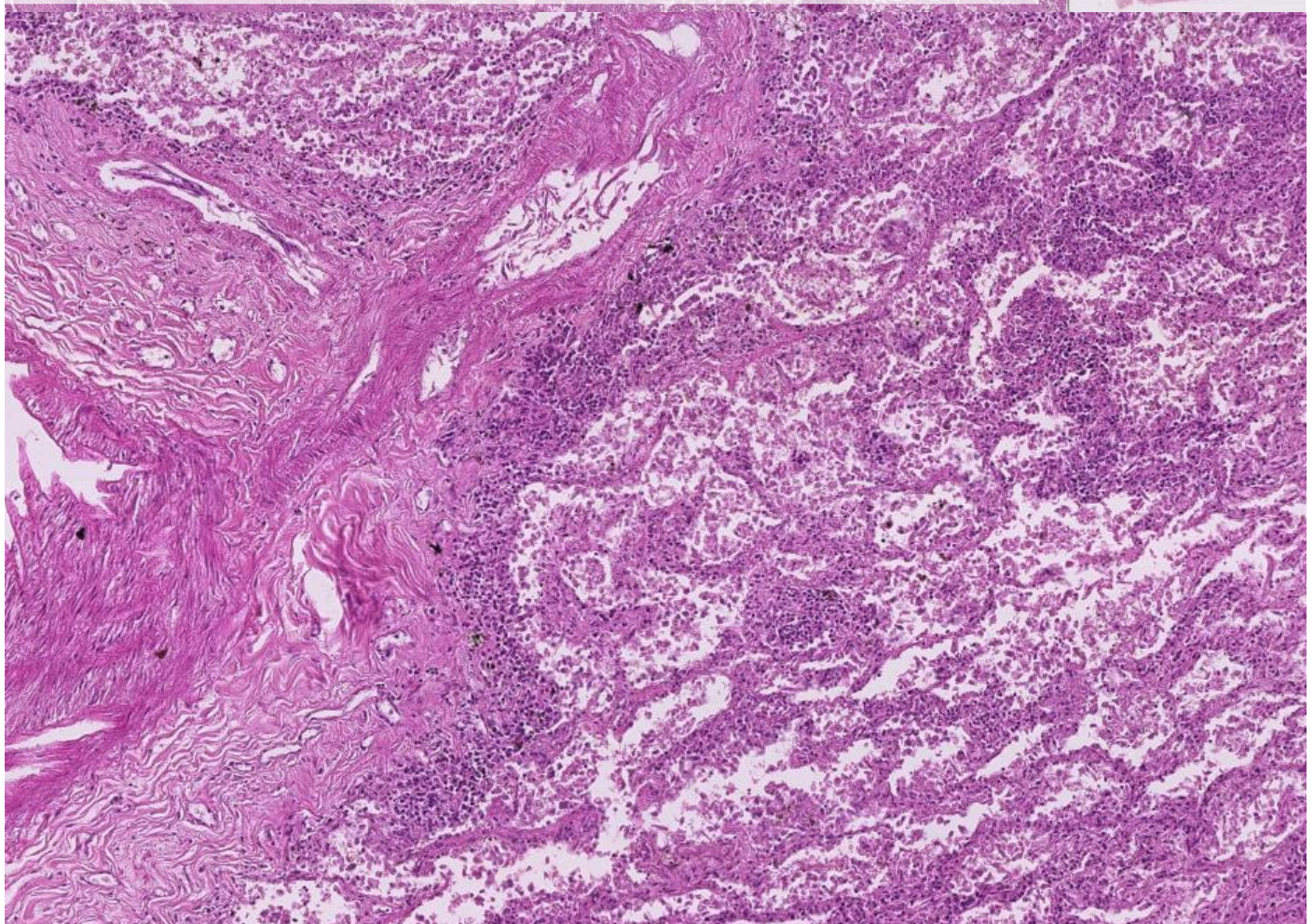
### III-5 Phlegmone der Muskulatur



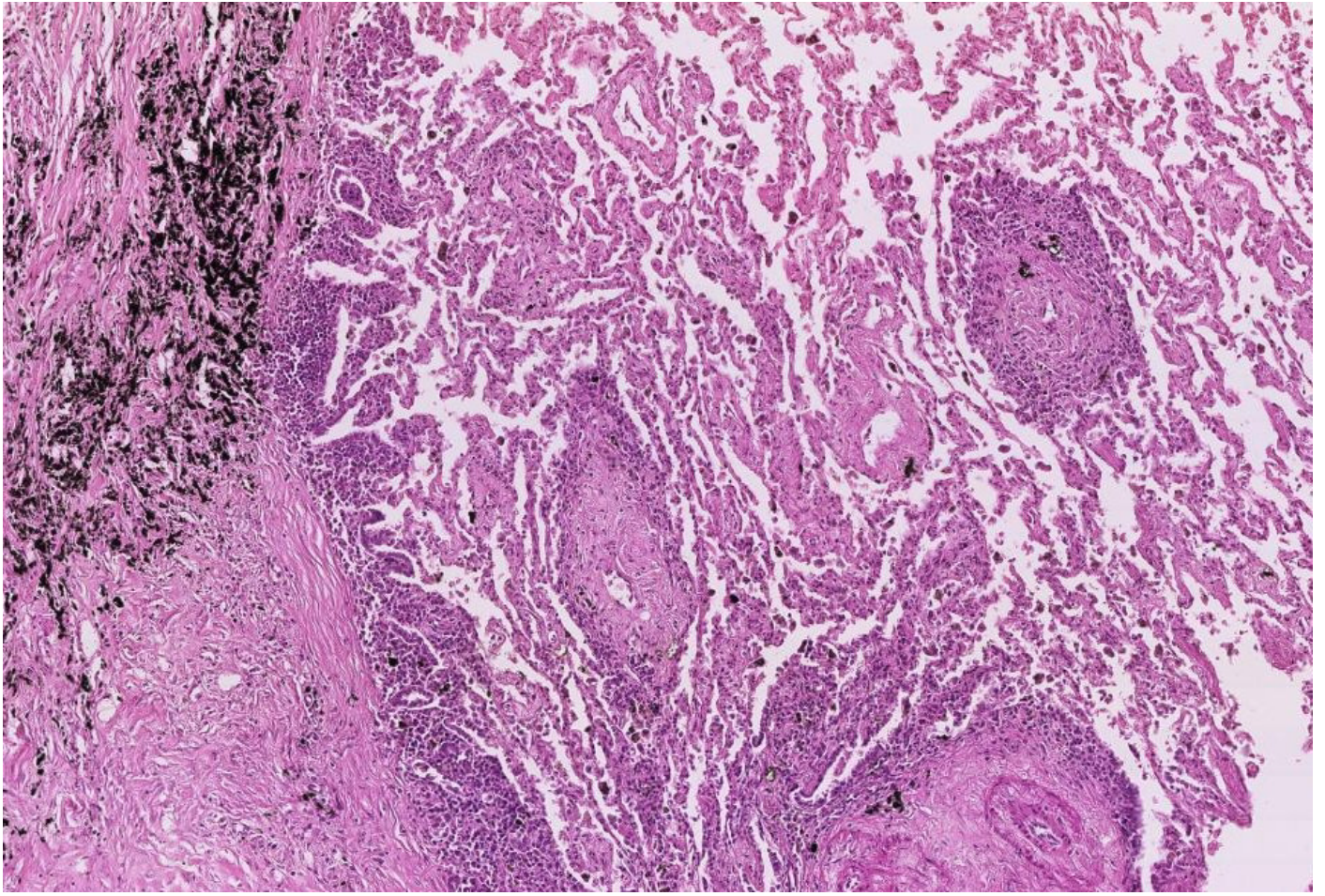
### III-6 Aktinomykose Lunge/Haut



Smart Zoom Technology © 2014 Smart In Media | Impressum







### III-7 Entzündliches Granulationsgewebe (Pleura)

