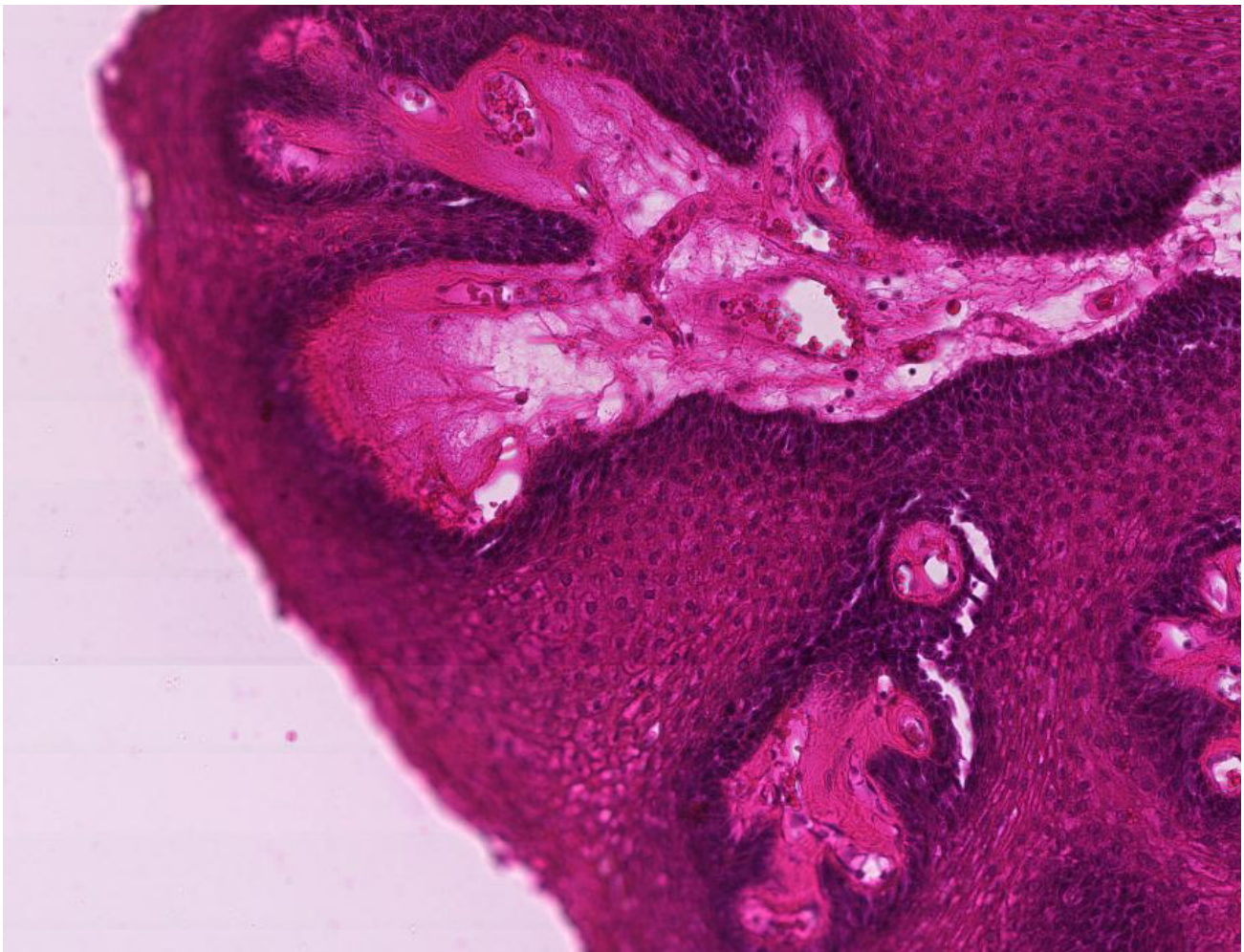
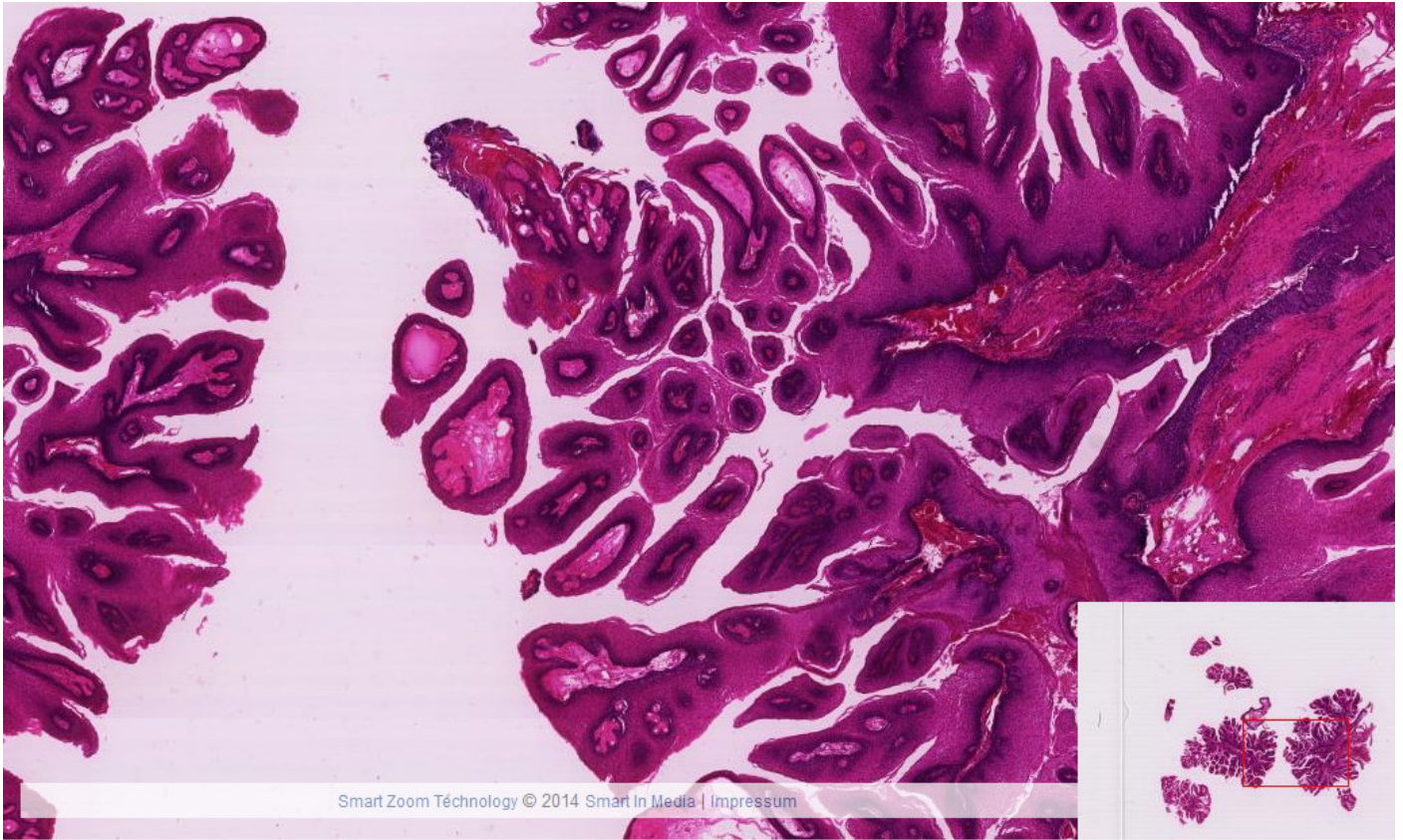
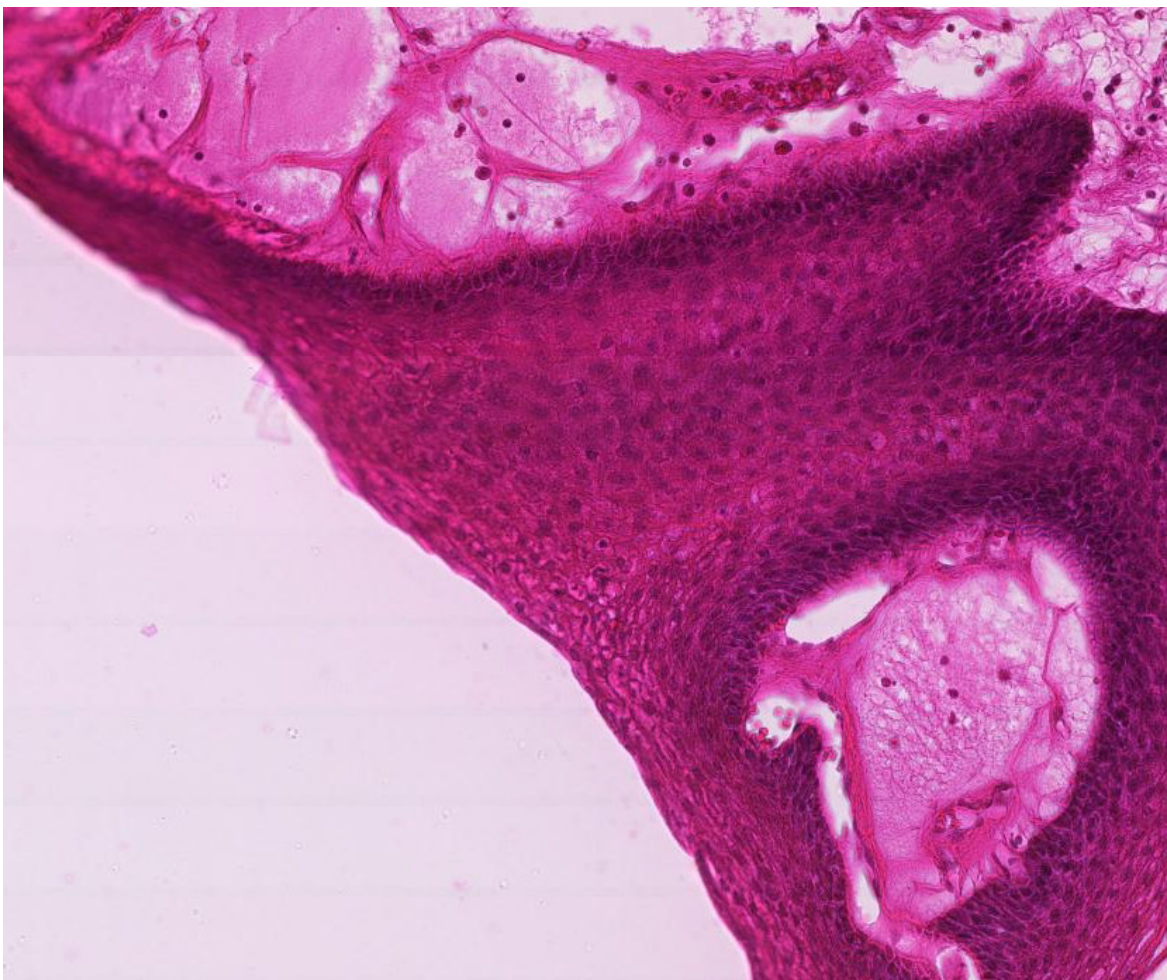
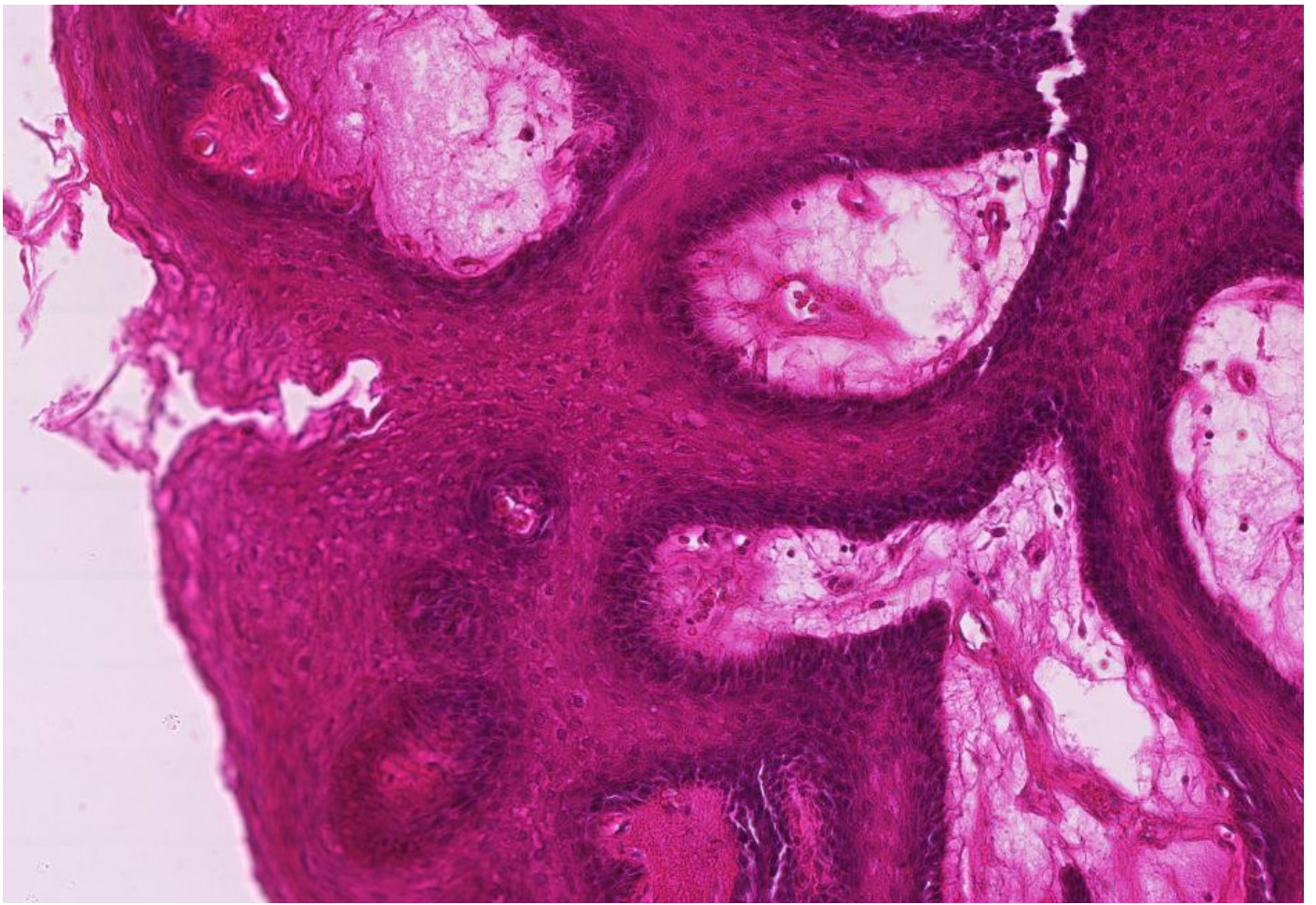


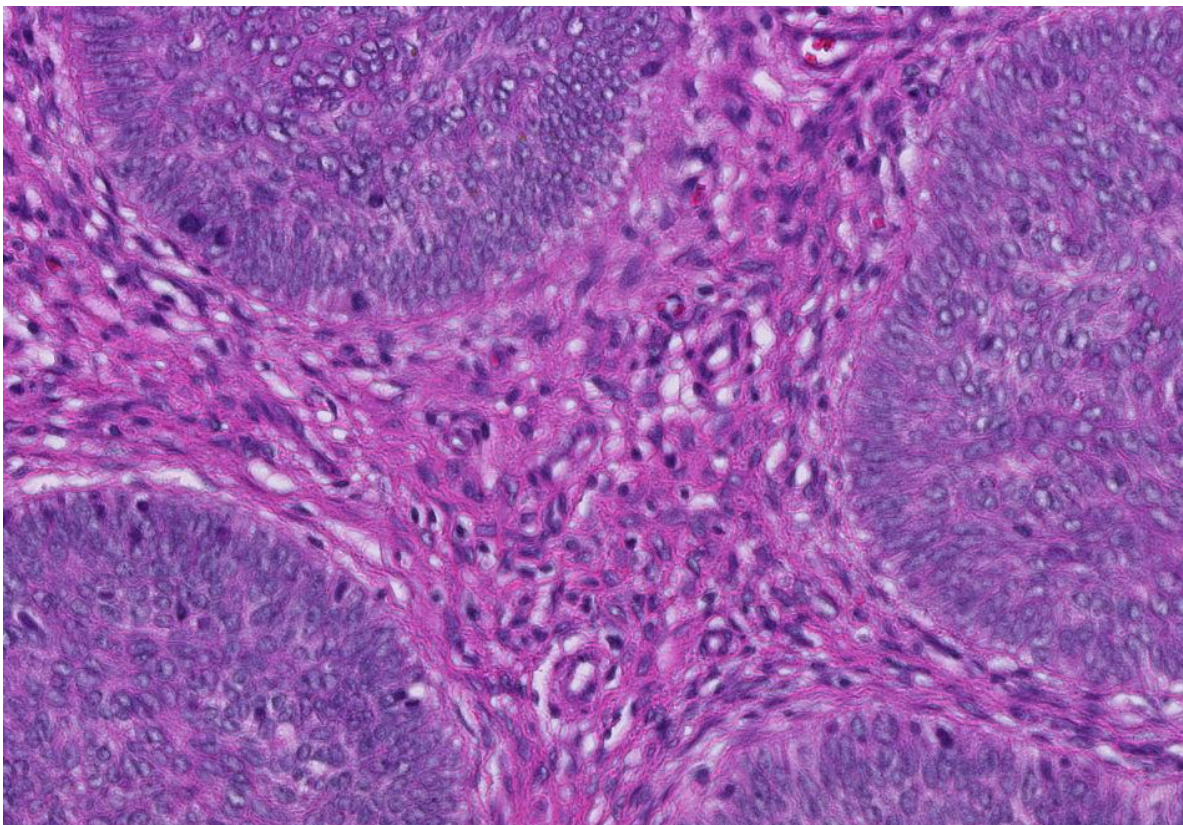
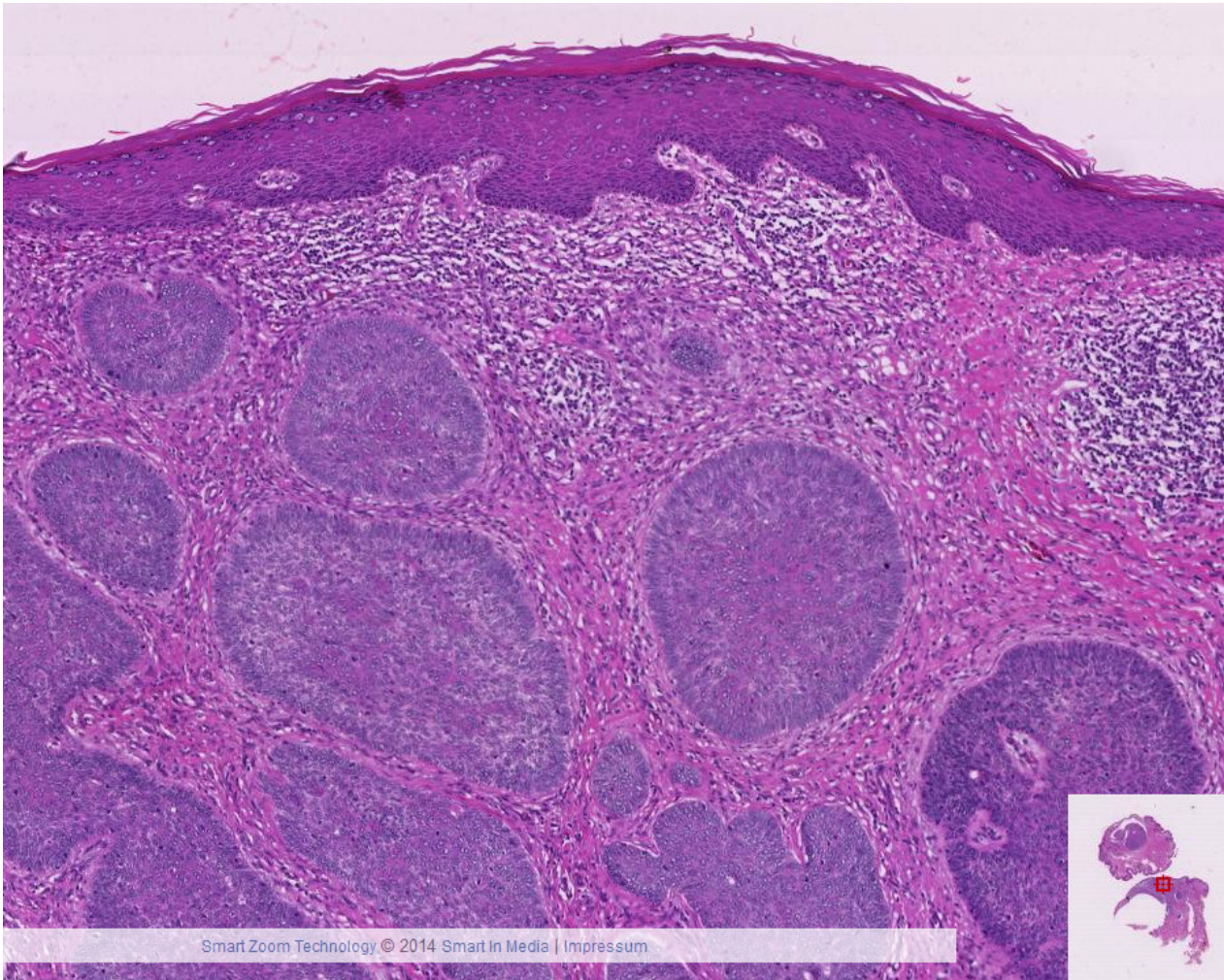
VI -1

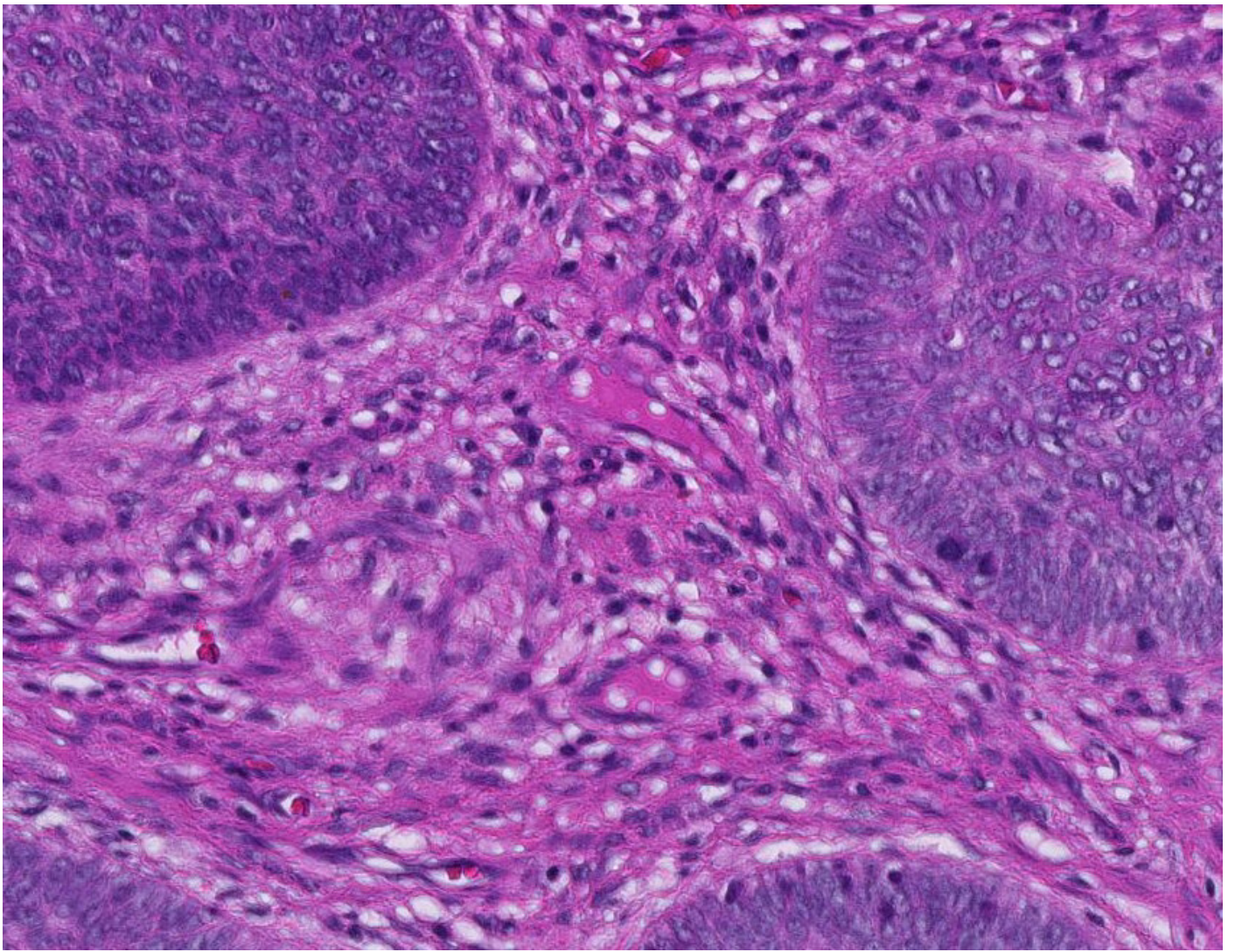
Plattenepithelpapillom



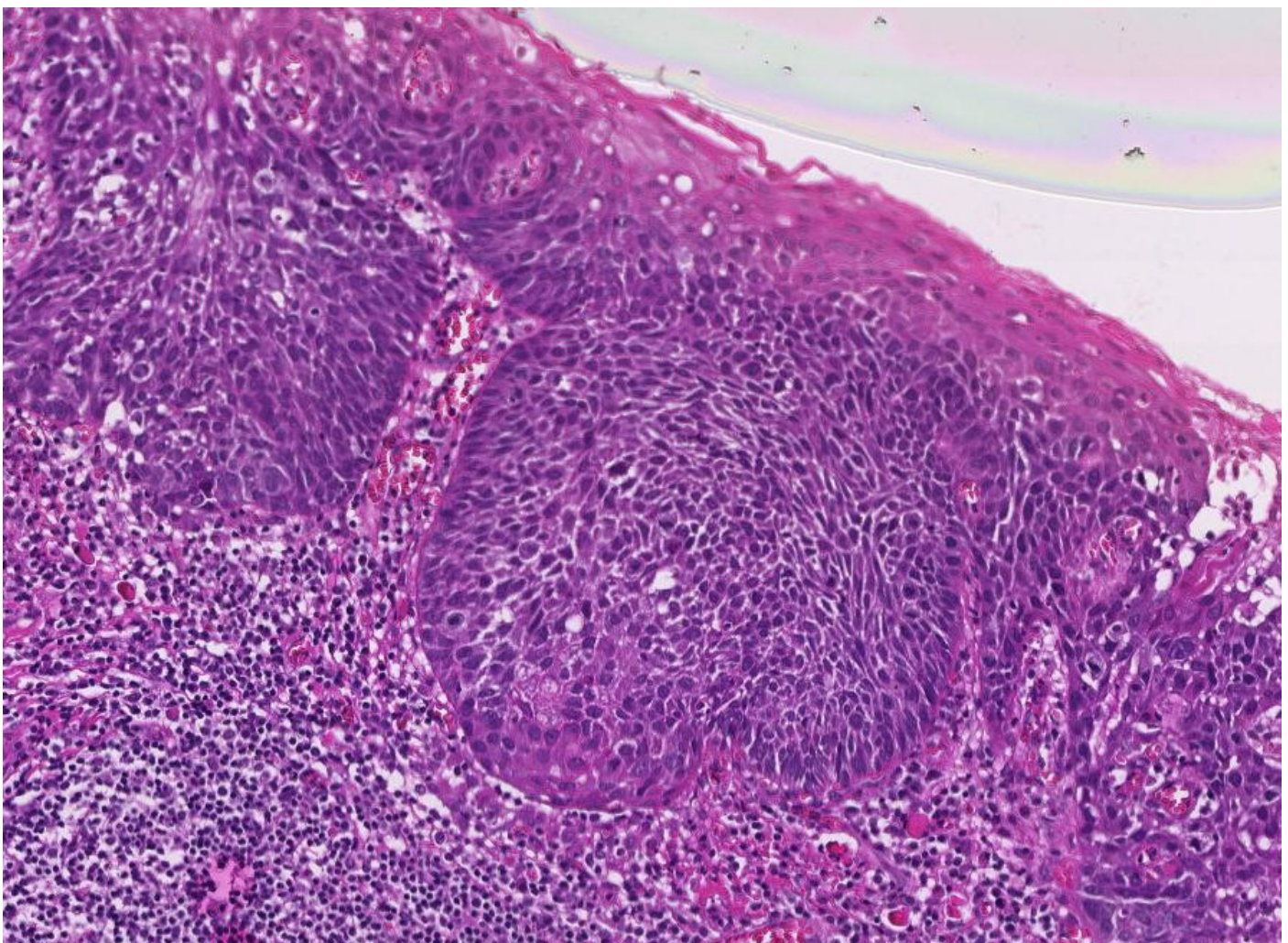
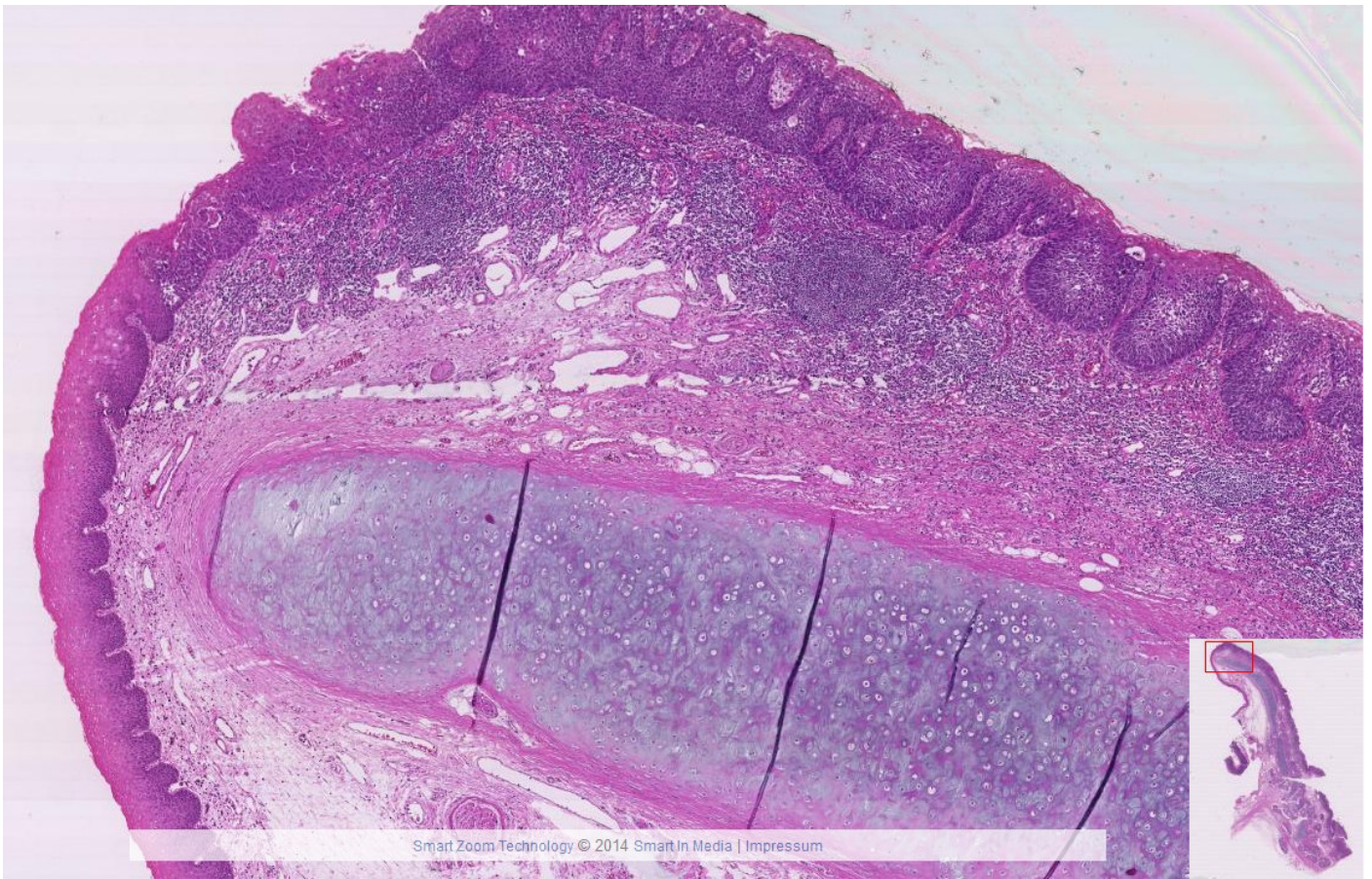


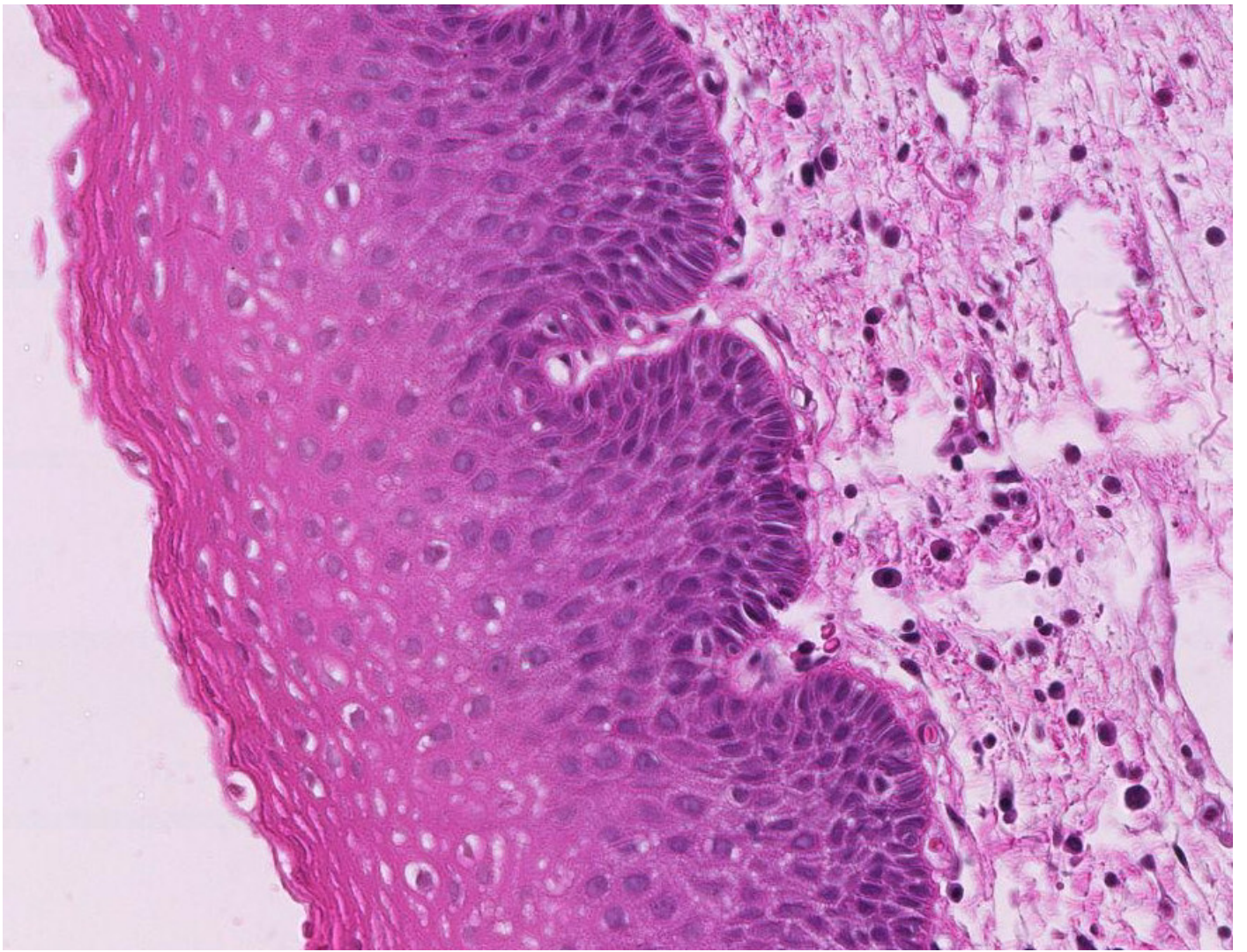
VI-2 Basaliom





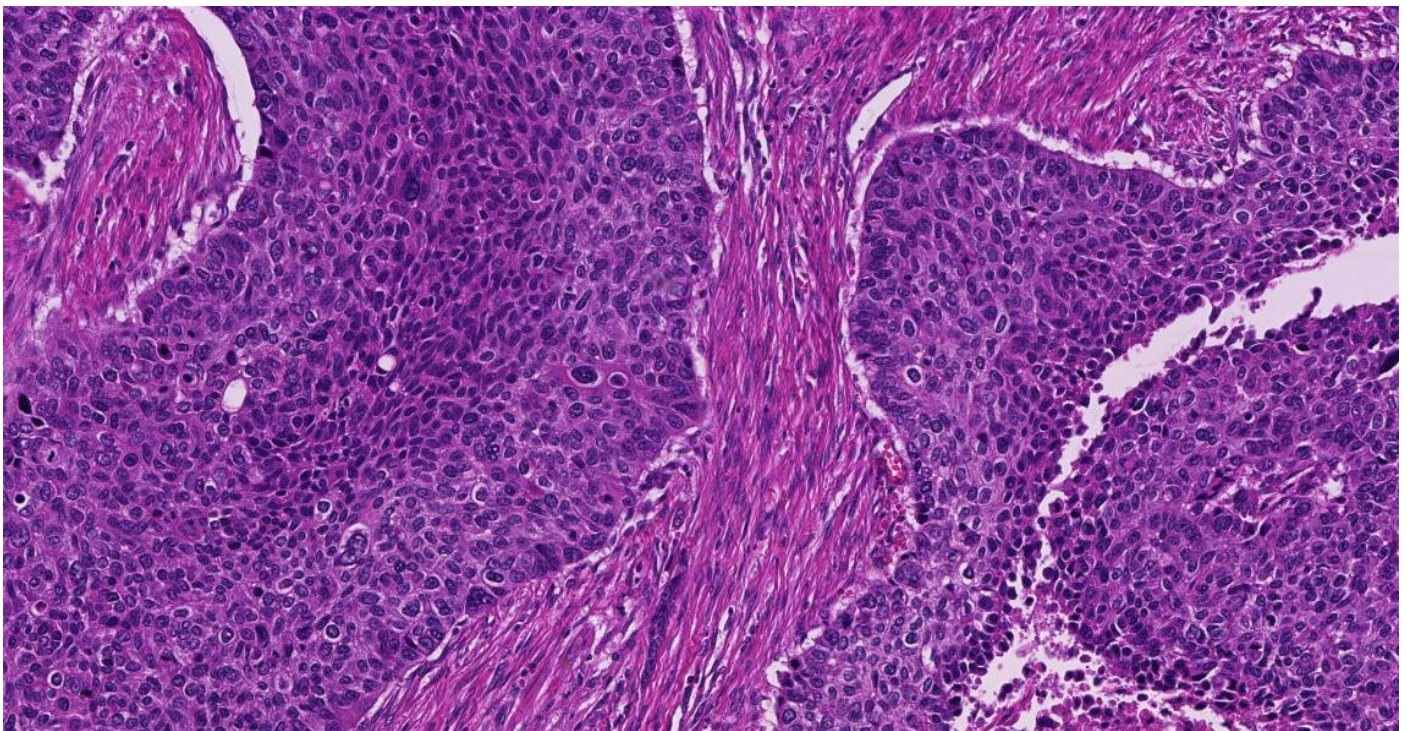
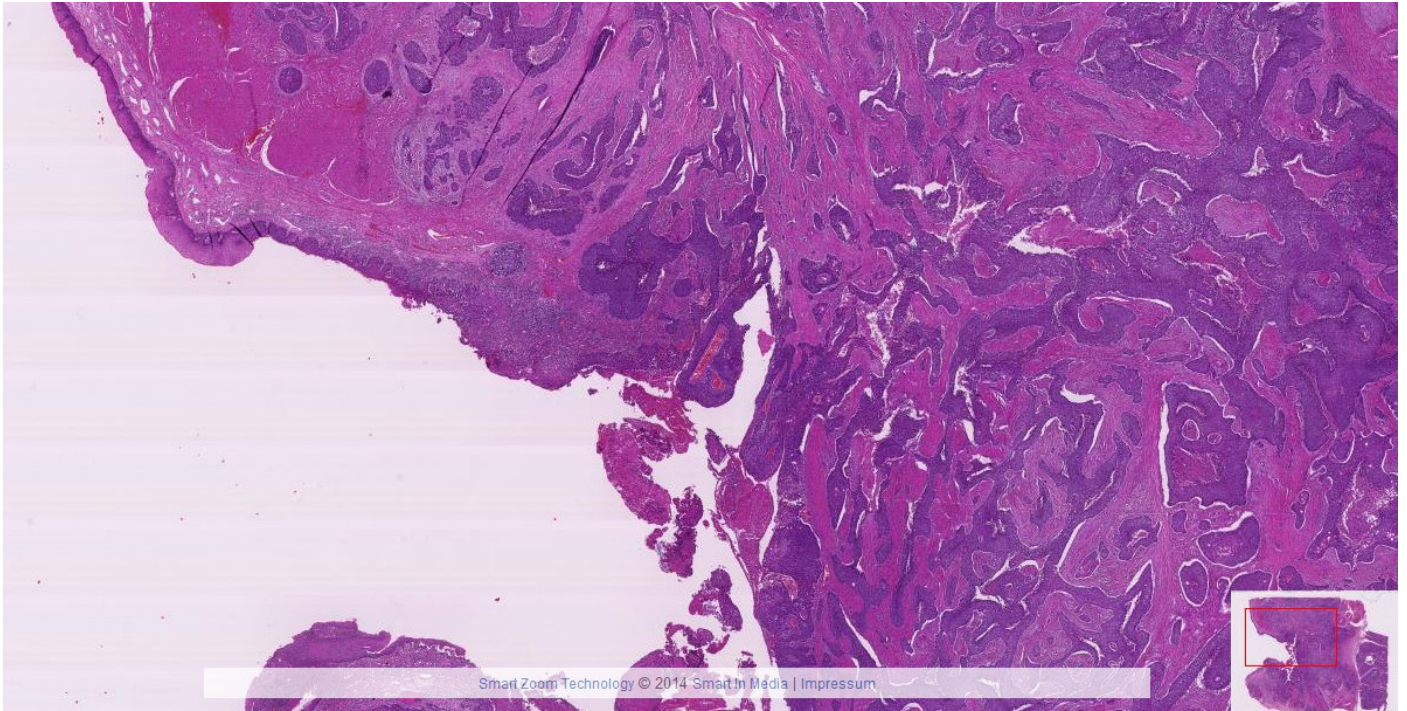
VI-3 Carcinoma in situ Epiglottis



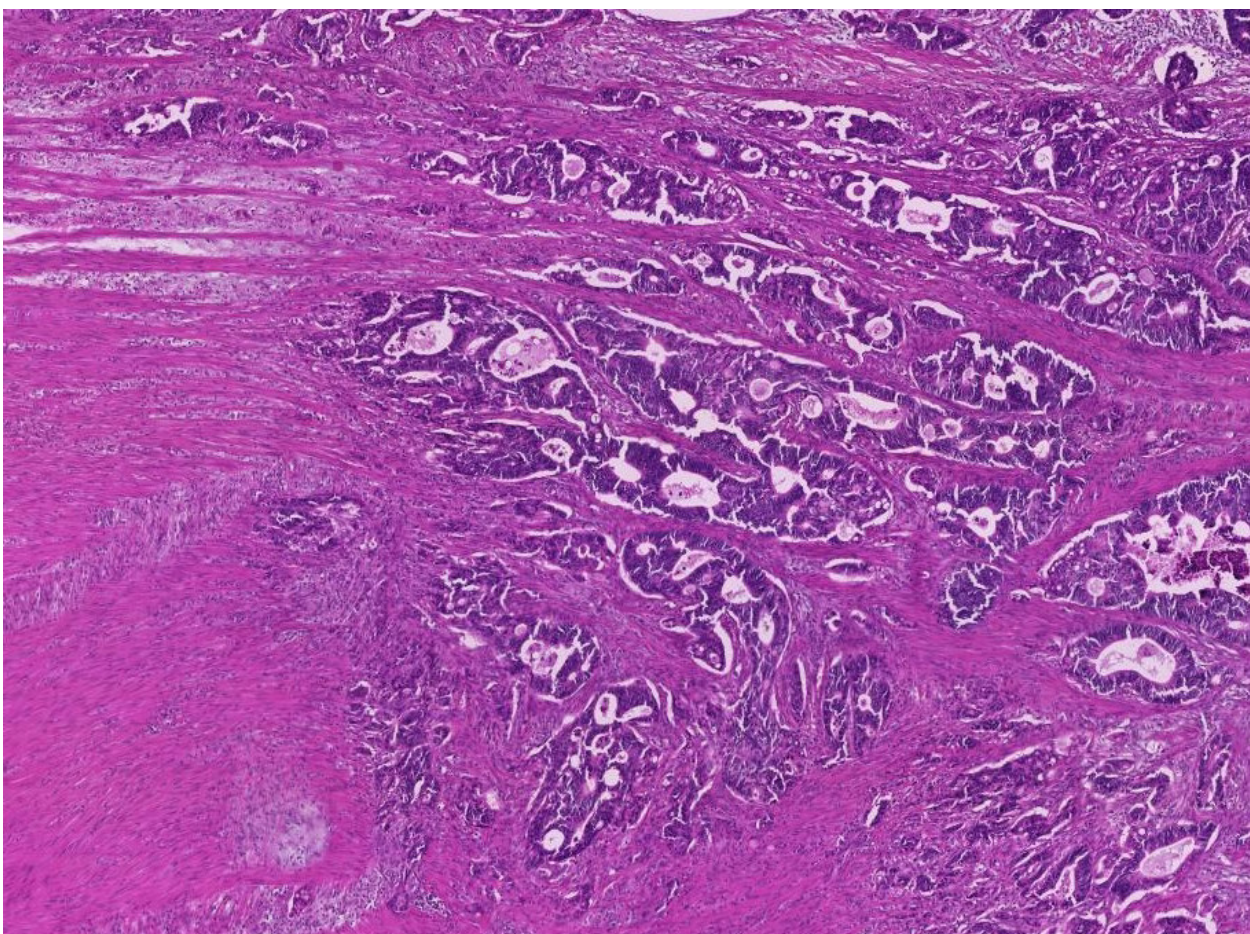
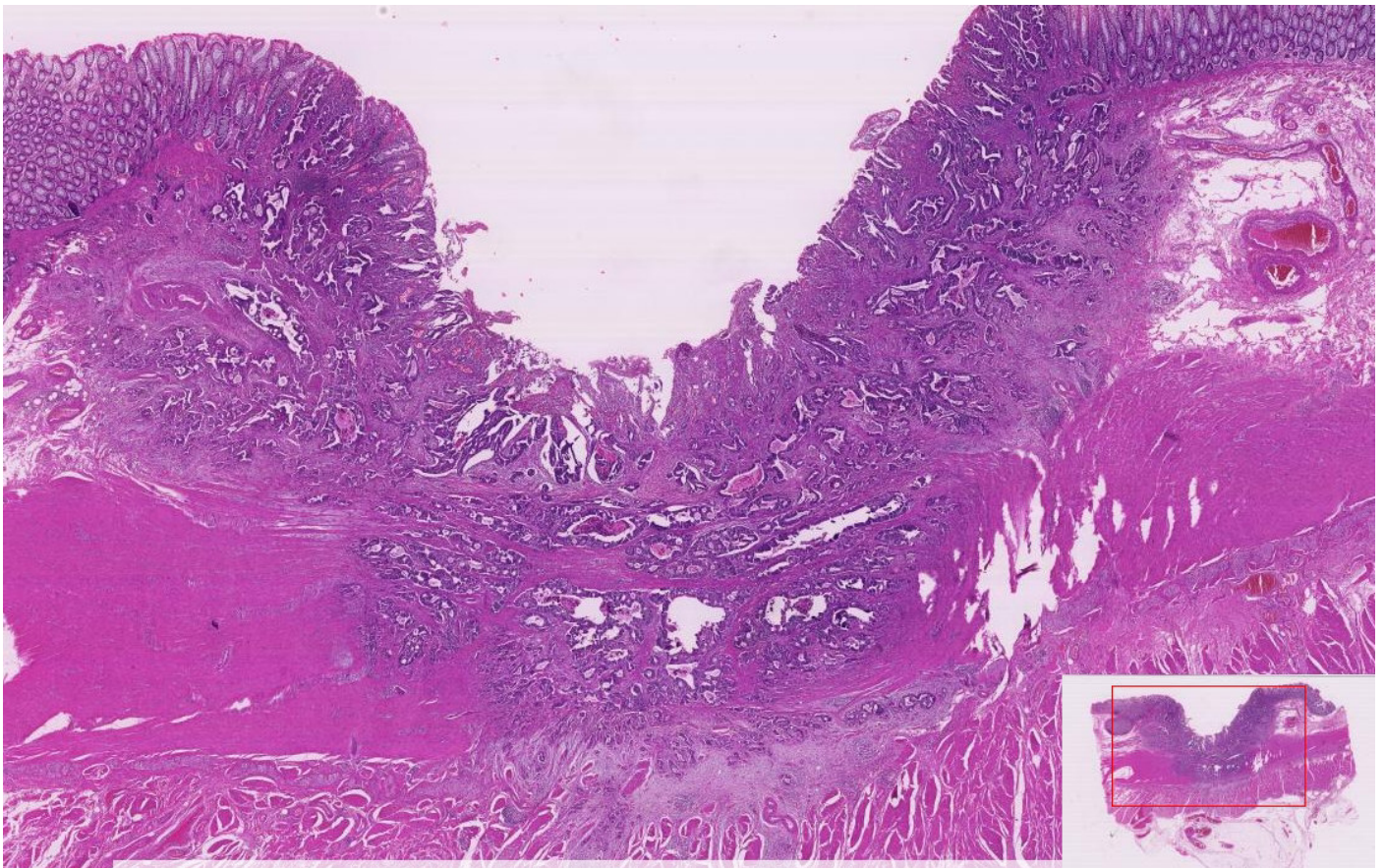


VI-4

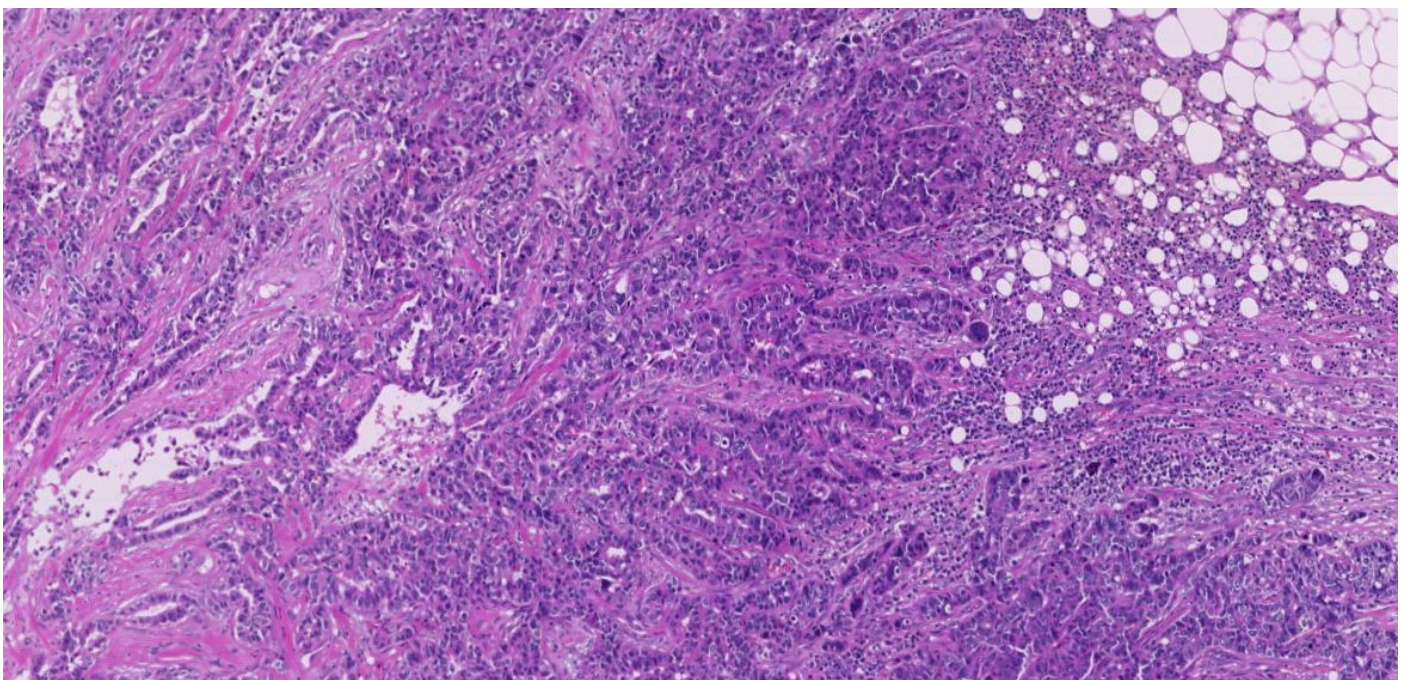
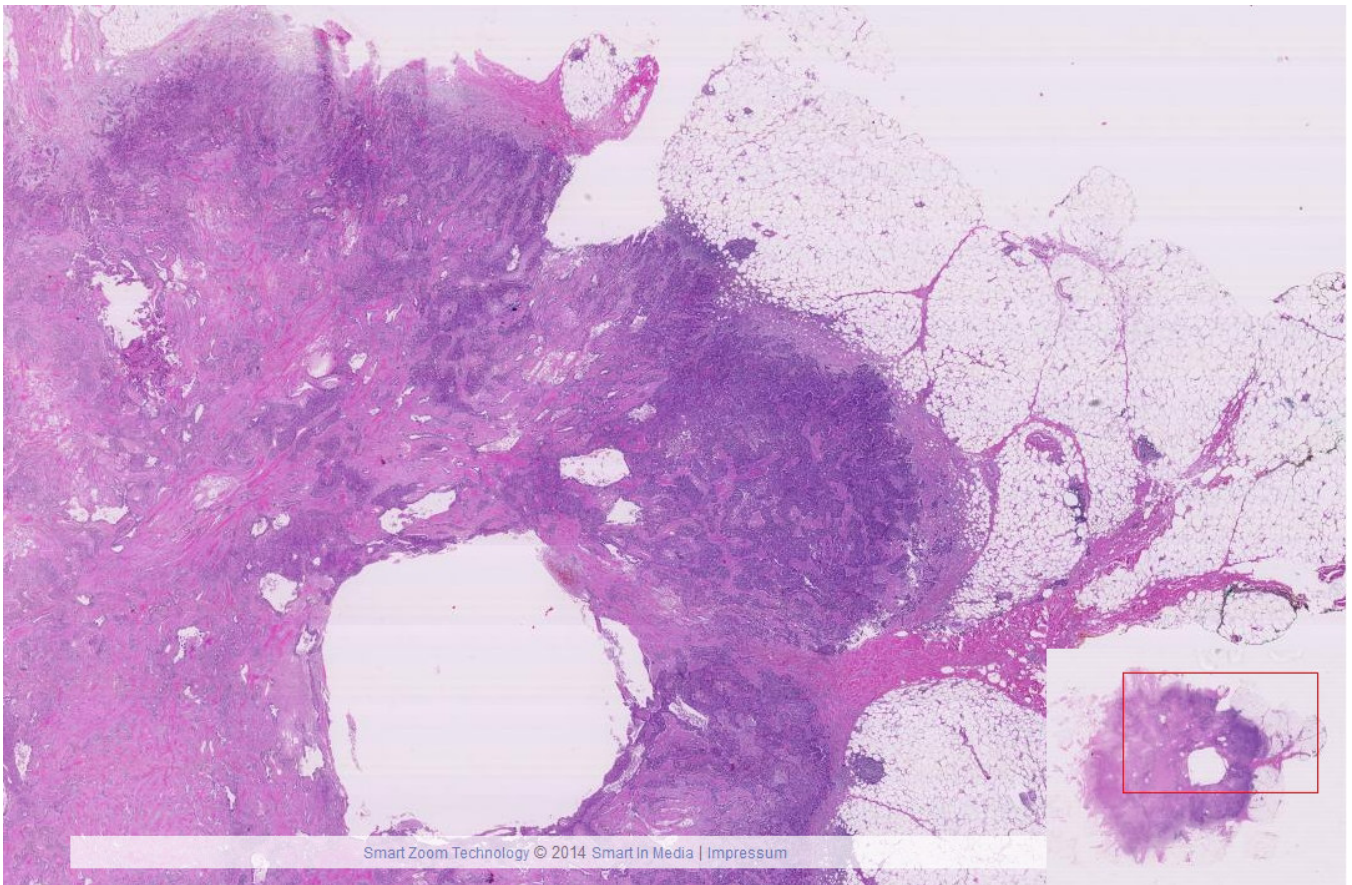
Plattenepithelkarzinom(Zunge)

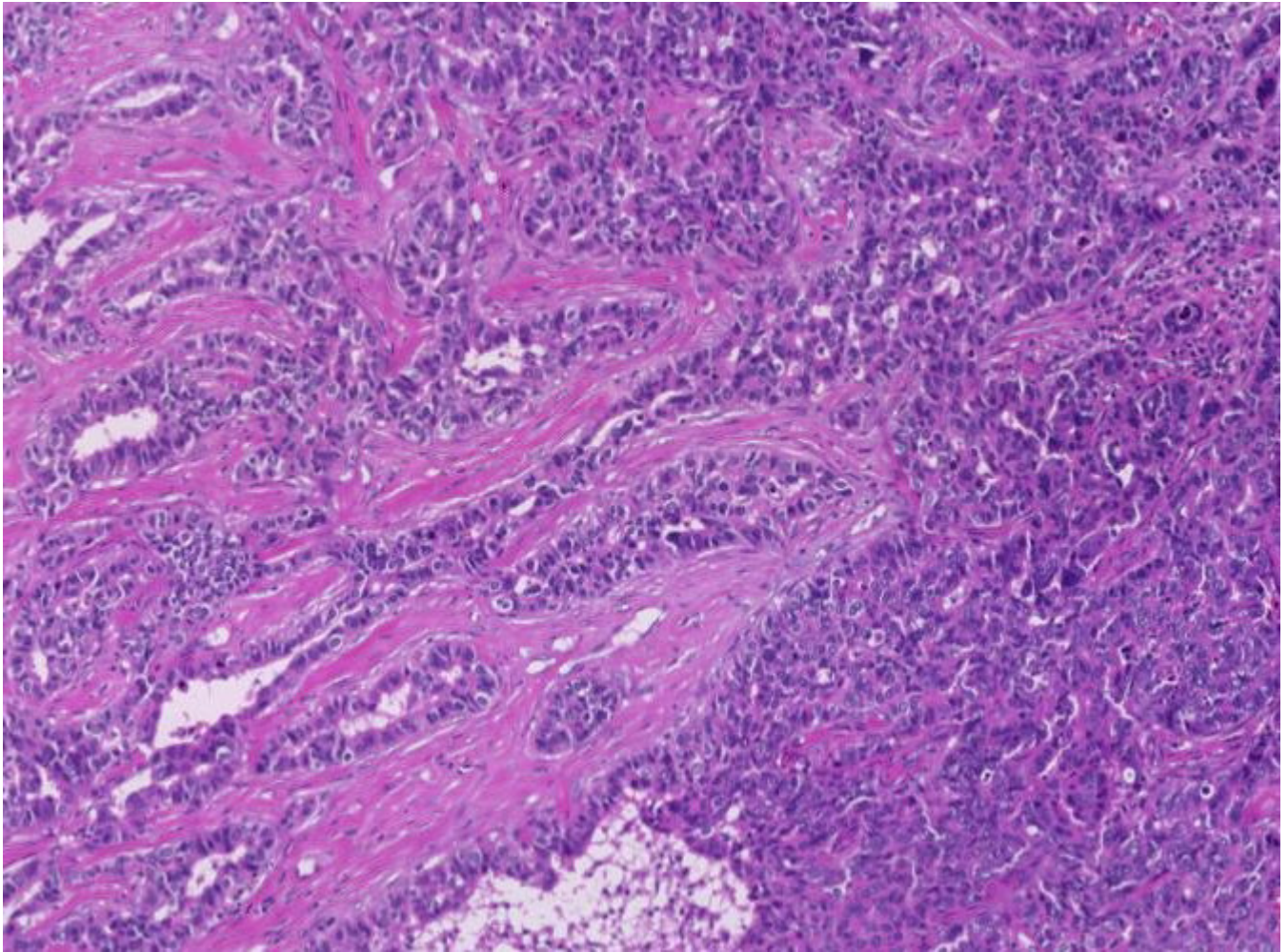


VI-5 Drüsenbildendes Karzinom (Dickdarm)

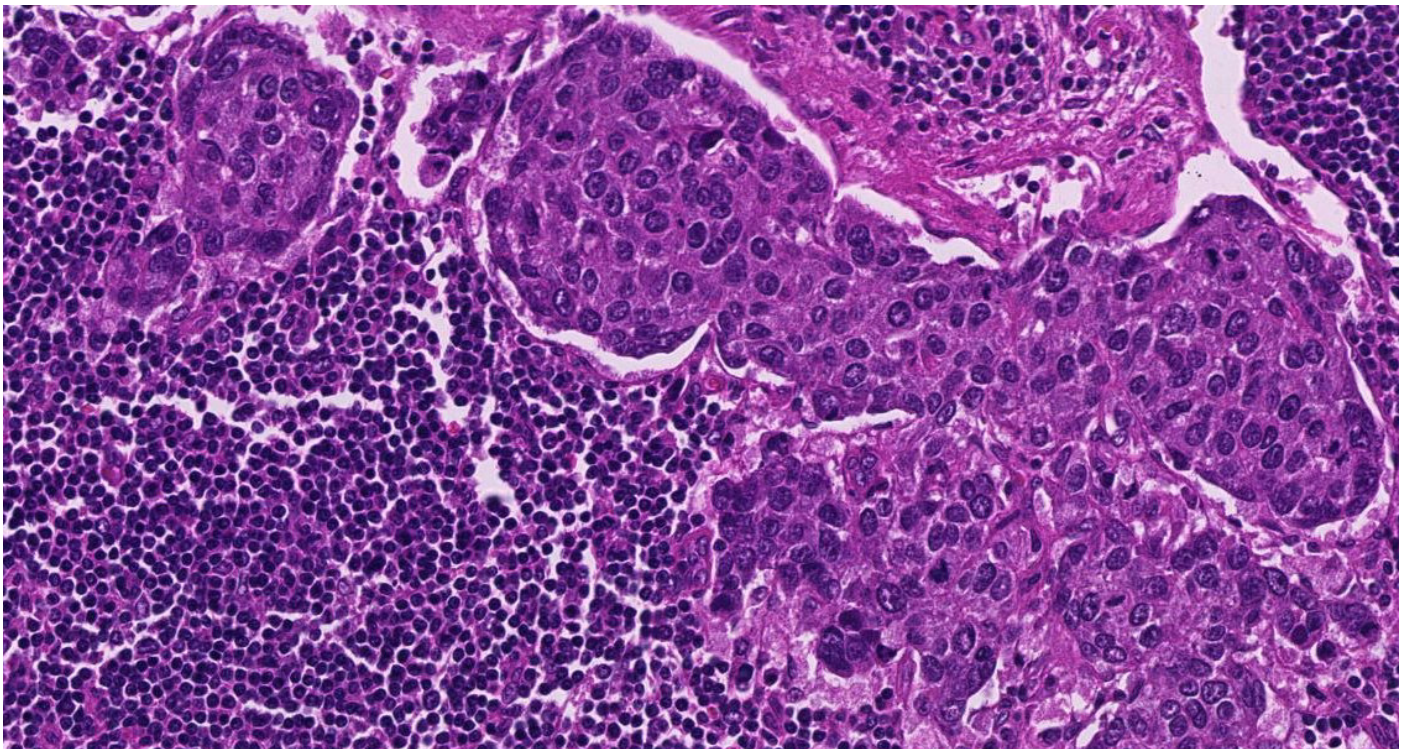
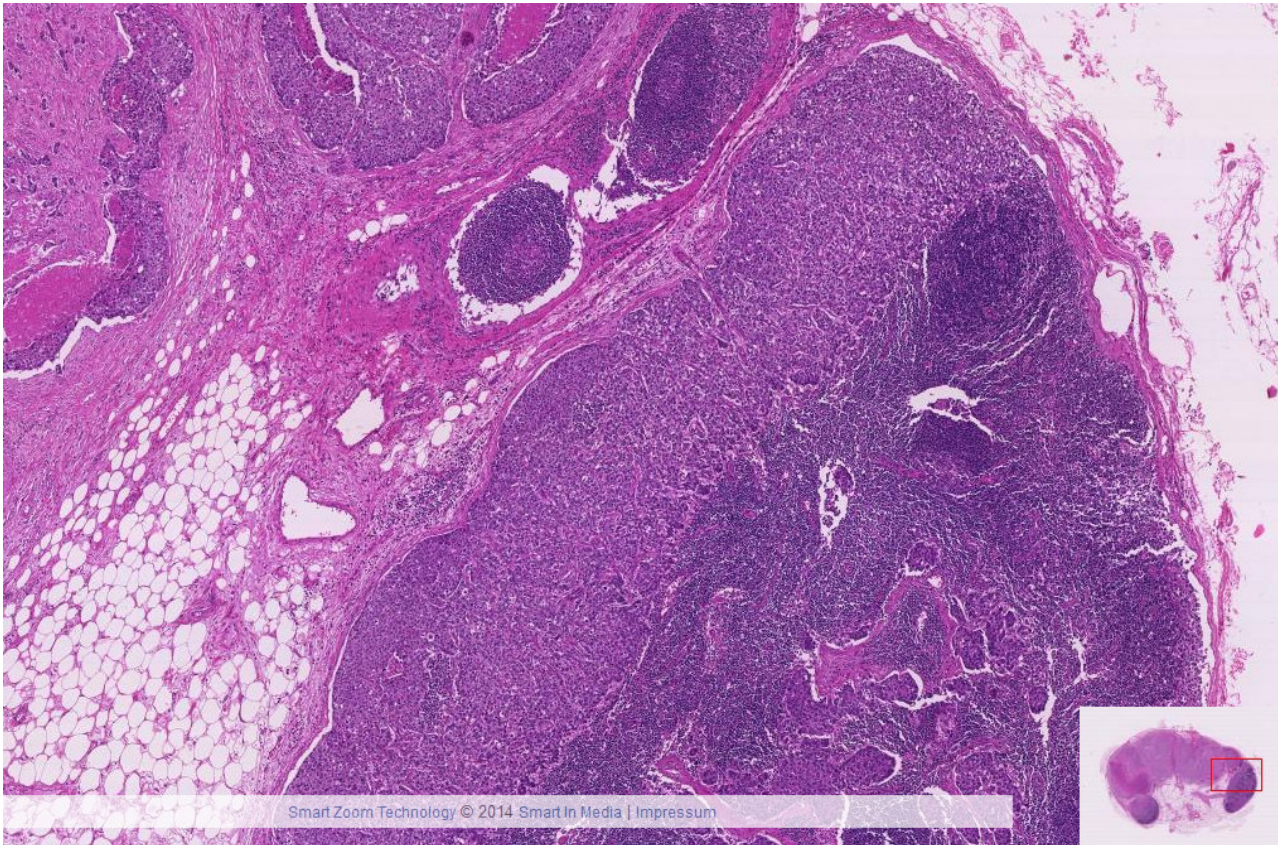


VI-6 Duktales invasives Mammakarzinom





VI-7 Karzinomatöse Lymphknotenmetastase



VI-8 Hämatogene Karzinommetastase (Leber)

